Check for updates

Consensus Document

VASCULAR MEDICINE

Vascular Medicine
1–26
© The Author(s) 2019
Article reuse guidelines:
sagepub.com/journals-permissions
DOI: 10.1177/1358863X18821816
journals.sagepub.com/home/vmj
SAGE

First International Consensus on the diagnosis and management of fibromuscular dysplasia

Heather L Gornik (Co-Chair)[1*], Alexandre Persu (Co-Chair)[2*], David Adlam[3,4], Lucas S Aparicio[5], Michel Azizi[6,7,8], Marion Boulanger[9], Rosa Maria Bruno[10], Peter de Leeuw[11], Natalia Fendrikova-Mahlay[1], James Froehlich[12], Santhi K Ganesh[12], Bruce H Gray[13], Cathlin Jamison[14], Andrzej Januszewicz[15], Xavier Jeunemaitre[16,17], Daniella Kadian-Dodov[18], Esther SH Kim[19], Jason C Kovacic[18], Pamela Mace[20], Alberto Morganti[21], Aditya Sharma[22], Andrew M Southerland[23], Emmanuel Touzé[9], Patricia van der Niepen[24], Jiguang Wang[25], Ido Weinberg[26], Scott Wilson[27,28], Jeffrey W Olin[18], and Pierre-Francois Plouin[6,7,8**], on behalf of the Working Group 'Hypertension and the Kidney' of the European Society of Hypertension (ESH) and the Society for Vascular Medicine (SVM)**

[1]Division of Cardiovascular Medicine, Department of Cardiovascular Medicine, University Hospitals Cleveland Medical Center and UH Harrington Heart and Vascular Institute, Cleveland, OH, USA
[2]Division of Cardiology, Department of Cardiovascular Diseases, Cliniques Universitaires Saint-Luc and Pole of Cardiovascular Research, Institut de Recherche Expérimentale et Clinique, Université Catholique de Louvain, Brussels, Belgium
[3]Department of Cardiovascular Sciences, Glenfield Hospital, Leicester, UK
[4]NIHR Leicester Biomedical Research Centre, Glenfield Hospital, Leicester, UK
[5]Hypertension Section, Internal Medicine Department, Hospital Italiano de Buenos Aires, Buenos Aires, Argentina
[6]Paris Descartes University, Paris, France
[7]Assistance-Publique Hôpitaux de Paris, Hôpital Européen Georges Pompidou, Hypertension Unit, Paris, France
[8]Institut national de la santé et de la recherche médicale, Centre d'Investigation Clinique 1418, Paris, France
[9]Normandie Université, UNICAEN, Inserm U1237, CHU Caen Normandie, Caen, France
[10]Department of Clinical and Experimental Medicine University of Pisa, Pisa, Italy
[11]Department of Medicine, Maastricht University Medical Center, Maastricht, The Netherlands
[12]Department of Internal Medicine, Frankel Cardiovascular Center, University of Michigan, Ann Arbor, MI, USA
[13]University of South Carolina School of Medicine/Greenville, Greenville, SC, USA
[14]Association belge de patients atteints de Dysplasie Fibromusculaire/FMD Groep België (FMD-Be), Brussels, Belgium
[15]Department of Hypertension, Institute of Cardiology, Warsaw, Poland
[16]APHP, Department of Genetics and Centre for Rare Vascular Diseases, Hôpital Européen Georges Pompidou, Paris, France
[17]INSERM, U970 – PARCC, University Paris Descartes, Sorbonne Paris Cité, Paris, France
[18]Zena and Michael A Wiener Cardiovascular Institute and Marie-Josée and Henry R. Kravis Center for Cardiovascular Health; Icahn School of Medicine at Mount Sinai, New York, NY, USA
[19]Division of Cardiovascular Medicine, Vanderbilt University Medical Center, Nashville, TN, USA
[20]Fibromuscular Dysplasia Society of America (FMDSA), North Olmsted, OH, USA
[21]Centro Fisiologia Clinica e Ipertensione, Policlinico Hospital, University of Milan, Milan, Italy
[22]Department of Medicine, Cardiovascular Medicine Division, University of Virginia, Charlottesville, VA, USA
[23]Department of Neurology, University of Virginia, Charlottesville, VA, USA
[24]Department of Nephrology & Hypertension Vrije Universiteit Brussel (VUB), Universitair Ziekenhuis Brussel (UZ Brussel), Brussels, Belgium
[25]Shanghai Institute of Hypertension and Center for Epidemiological Studies and Clinical Trials, Ruijin Hospital, Shanghai Jiaotong University School of Medicine, Shanghai, China
[26]Vascular Medicine Section and Vascular Center, Harvard Medical School, Massachusetts General Hospital, Boston, MA, USA
[27]Monash University (Central Clinical School of Medicine), Melbourne, VIC, Australia
[28]Department of Renal Medicine, Alfred Health, Melbourne, VIC, Australia

*These authors contributed equally to this work.
**These authors contributed equally to this work.

This contribution is being co-published in the following journals: *Journal of Hypertension* and *Vascular Medicine*. There will be minor differences in the version published in *Vascular Medicine* due to copy-editing differences.

Corresponding author:
Heather L Gornik, Division of Cardiovascular Medicine, Department of Cardiovascular Medicine, University Hospitals Cleveland Medical Center and UH Harrington Heart and Vascular Institute, 11000 Euclid Avenue, Cleveland, Ohio, 44106, USA.
Email: heather.gornik@uhhospitals.org
Twitter: @heatherlgornik

Abstract

This article is a comprehensive document on the diagnosis and management of fibromuscular dysplasia (FMD), which was commissioned by the working group 'Hypertension and the Kidney' of the European Society of Hypertension (ESH) and the Society for Vascular Medicine (SVM). This document updates previous consensus documents/scientific statements on FMD published in 2014 with full harmonization of the position of European and US experts. In addition to practical consensus-based clinical recommendations, including a consensus protocol for catheter-based angiography and percutaneous angioplasty for renal FMD, the document also includes the first analysis of the European/International FMD Registry and provides updated data from the US Registry for FMD. Finally, it provides insights on ongoing research programs and proposes future research directions for understanding this multifaceted arterial disease.

Keywords

aneurysm, cervical artery dissection, fibromuscular dysplasia (FMD), percutaneous angioplasty, pressure gradients, renovascular hypertension, spontaneous coronary artery dissection

Introduction

Fibromuscular dysplasia (FMD) is a non-atherosclerotic arterial disease that is characterized by abnormal cellular proliferation and distorted architecture of the arterial wall. FMD primarily manifests as beaded (multifocal) or focal lesions in medium or small-sized arteries, though the clinical phenotype of FMD has recently been expanded to include arterial dissection, aneurysm, and tortuosity.[1,2] FMD most commonly affects the renal and extracranial carotid and vertebral arteries, but nearly all arterial beds may be affected, and multivessel involvement is common. Approximately 80–90% of patients with FMD are women.[2,3] Though less common, men also develop FMD and may have a more aggressive course with a higher frequency of aneurysms and dissections.[3] Though initially described in 1938 and classified according to angiographic and histopathological findings in the 1960s and 1970s, the greatest advances in the understanding of the pathophysiology and natural history of FMD have come in the past decade and have been driven by data from international patient registries and multicenter research collaborations.[2,4] In 2014, multispecialty groups from Europe and the United States published consensus statements regarding FMD.[5,6] Although these documents were developed independently, there were many similarities in interpretation of the medical literature and state of the clinical science – both documents representing initial attempts to develop a multispecialty consensus on a standardized approach to this disease.

Building upon the prior European and US documents, as well as international symposia held in Cleveland, Ohio, USA (May 18–19, 2017) and Brussels, Belgium (February 22–24, 2018), a writing committee was commissioned by the Society for Vascular Medicine (SVM) and the working group 'Hypertension and the Kidney' of the European Society for Hypertension (ESH) to create a single expert consensus document regarding FMD. The focus of this document will be review of new medical literature since the 2014 statements, summary of current international research efforts, and coordination of expert opinion into a single international expert consensus regarding the etiology, diagnostic approach, and management of FMD. A summary of consensus points, discussed throughout the document, is provided in Supplemental Table 1. Although there has been a recent expansion of published research in this field, including data from observational registries of patients with FMD, the authors acknowledge that level I data in this field are limited and the majority of points are based upon the expert consensus of the international panel of writing committee members. It is the intent of the writing committee that this international consensus document, including identification of research priorities, will lead to future high-quality research efforts, additional observational studies, and randomized controlled trials, and that these data will be incorporated into a future international guideline document.

Although the writing committee recognizes the importance of FMD as a cause of renovascular hypertension in children, the scope of this document is focused on FMD in adult patients. Writing committee members were selected by each society based upon extensive experience in the care of patients with FMD and/or research contributions to the field, including participation in international FMD registries. This document has been peer reviewed by members of both the ESH and SVM, and this final expert consensus has been endorsed by both the working group 'Hypertension and the Kidney' of the ESH and the Board of Trustees of the SVM.

Definition, classification, and differential diagnosis

Definition of FMD

The European consensus definition of FMD provides a baseline description of what constitutes FMD: An idiopathic, segmental, non-atherosclerotic and non-inflammatory disease of the musculature of arterial walls, leading to stenosis of small and medium-sized arteries.[6] Lesions of FMD can be either symptomatic or clinically silent and can be either hemodynamically significant or not. The diagnosis of FMD requires evaluation for other disease states on the differential diagnosis, such as arterial spasm, standing waves, atherosclerosis, and monogenic and inflammatory arterial diseases, among other entities which are discussed in detail below.

Classification of FMD

Although previously used, the consensus of this writing committee is that the histopathological classification of

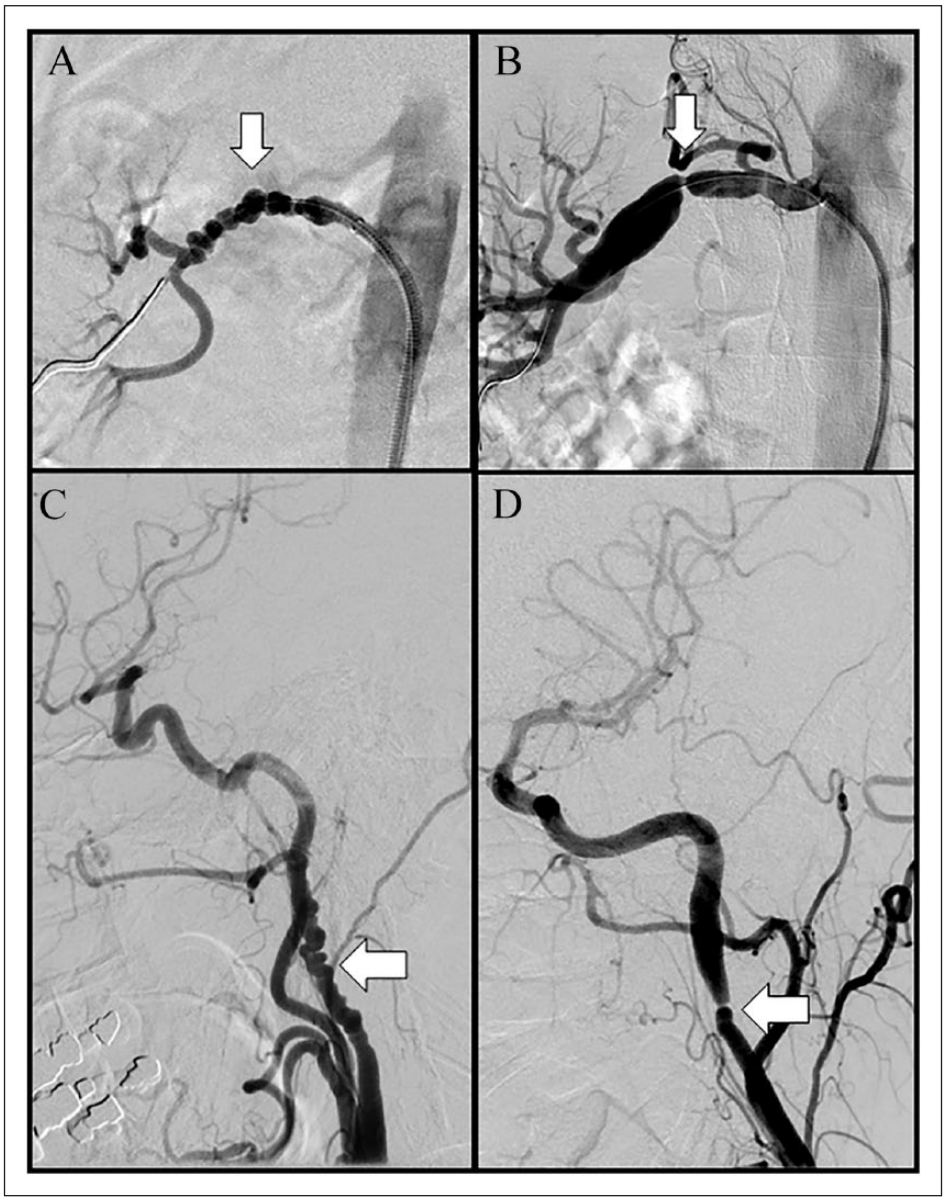

Figure 1. Angiographic images of multifocal and focal FMD of the renal and internal carotid arteries (arrows). (A) Multifocal FMD of the renal artery; (B) severe FMD-related focal stenosis of the renal artery with post-stenotic dilatation; (C) multifocal FMD of the internal carotid artery; (D) focal FMD of the internal carotid artery.
Panel D is reprinted with permission from ref. 5, https://www.ahajournals.org/doi/abs/10.1161/01.cir.0000442577.96802.8c.
FMD, fibromuscular dysplasia.

FMD is no longer applicable in modern clinical practice.[7–9] FMD may result in two types of angiographic appearance (Figure 1): (1) focal FMD, which may occur in any part of the artery; or (2) multifocal FMD, alternating areas of stenosis and dilation (the so-called 'string of beads'), which usually occurs in the mid and distal portions of the artery.[5,10] This morphology most often occurs in the renal and carotid arteries but may occur in any artery in the body.[2] This classification of FMD does not refer to histology as tissue is rarely available since the advent of endovascular therapy. The 2014 AHA classification of FMD is similar to the 2014 European consensus document, though the two documents differ with respect to the use of the terms 'focal FMD' (AHA) or 'unifocal FMD' (European).[5,6] This international consensus now recommends angiographic classification of FMD using the terms 'focal FMD' and 'multifocal FMD'.

CONSENSUS POINT: Arterial lesions of FMD should be classified according to angiographic appearance as *focal FMD* or *multifocal FMD*.

Stenosis, aneurysm, dissection, arterial tortuosity

FMD is primarily a stenotic disease (with lesions classified by angiographic appearance as above). It is also increasingly recognized that aneurysm, dissection, and arterial tortuosity occur with increased frequency in affected patients.[1,11] Recent literature has suggested that arterial tortuosity occurs frequently among patients with

FMD.[12] Tortuosity of the internal carotid artery (ICA) leading to an S-curve has been described among patients with FMD as a distinct morphological entity of the mid to distal portion of the ICA formed by an elongation causing two markedly tortuous turns in the shape of the letter 'S'.[12] In one study, the S-curve was identified on carotid duplex ultrasound in 32% of patients with FMD of the renal, carotid, and/or vertebral arteries.[12] In addition to the S-curve, other manifestations of carotid and vertebral artery tortuosity have been described, though not specifically among patients with FMD.[13–15] Tortuosity has also been reported in other arterial beds, including the coronary arteries. In a study from the Mayo Clinic, coronary tortuosity was defined by the presence of three or more consecutive curvatures of 90° to 180° measured at end-diastole in a major epicardial coronary artery ⩾ 2 mm in diameter.[16] Severe tortuosity was defined as two or more consecutive curvatures of ⩾ 180° in a major epicardial coronary artery ⩾ 2 mm in diameter. It was shown that there was a higher rate of recurrence of spontaneous coronary artery dissection (SCAD) among those patients with a high coronary tortuosity score. Other definitions of coronary artery tortuosity have been proposed.[17,18]

Nevertheless, it is important to recognize that the presence of aneurysms, dissections, or tortuosity in the absence of a focal or multifocal FMD stenotic lesion does not suffice to establish a diagnosis of FMD. Arterial aneurysm, dissection, and tortuosity are not unique to FMD and have been reported in multiple other vascular diseases.[19,20] However, if the patient has a focal or multifocal FMD lesion in one vascular bed and a documented aneurysm, dissection, or tortuosity in another vascular bed, it is the consensus of the writing committee that the patient be considered to have FMD in the vascular bed with the focal or multifocal lesion, as well as FMD involvement of the vascular bed with aneurysm, dissection, or tortuosity (i.e. multivessel FMD).[1,5] This point is of importance to allow for standardization of taxonomy in current FMD patient registries and future research studies.

CONSENSUS POINT: The presence of at least one focal or multifocal arterial lesion is required to establish the diagnosis of FMD. The presence of aneurysm, dissection, or tortuosity alone is inadequate to establish the diagnosis.

CONSENSUS POINT: If a patient has a focal or multifocal lesion in one vascular bed to establish the diagnosis of FMD, the presence of aneurysm, dissection, or tortuosity in another/other vascular beds is considered multivessel involvement of all affected vascular beds.

Etiological factors and genetics of FMD

Although a variety of genetic, mechanical, and hormonal factors have been proposed, the cause of FMD remains poorly understood. The development of FMD is likely related to a combination of genetic and environmental factors.[21]

Genetics of FMD

FMD appears to be both sporadic and familial in a subset of patients, with autosomal dominant inheritance suggested in some families.[21,22] However, it is important to note that in modern Registry studies, only a minority of patients (1.9–7.3%) with FMD report an affected family member.[2,4] Traditional family-based analyses have been hampered by the relatively low frequency of well-characterized multiplex pedigrees, incomplete penetrance (~0.5) and underdiagnosis of FMD, particularly of subclinical disease.[22–25] Previous studies which assessed genes associated with other known arteriopathies, such as those underlying aortic aneurysm and dissection, have not identified any clear association patterns between these genes and FMD.[26,27] Along with the high prevalence of asymptomatic FMD (~3–6%) and the influence of environmental modifiers (e.g. female hormones, lifetime mechanical stress, tobacco use), a complex genetic basis for FMD is suspected and provides a rationale for genetic association studies.[4,28,29] A genome-wide association study identified a common genetic risk variant: a single nucleotide polymorphism (SNP) rs9349379-A, in the *PHACTR1* locus (6p24), conferring an odds ratio (OR) of ~1.4 for FMD.[30] The risk variant resides within an intron of the *PHACTR1* gene that is associated with PHACTR1 transcript expression levels in dermal fibroblasts and may have direct effects on vascular development when tested in a zebrafish model of gene expression knock-down.[30] Further data suggest that the same SNP is located at the site of an enhancer in aortic tissue and that it regulates endothelin-1 expression.[31] Endothelin-1 has pleiotropic vascular effects on vascular tone and arterial remodeling. Interestingly, the *PHACTR1* FMD rs9349379-A risk-allele is associated with cervical artery dissection (CeAD), hypertension, and migraine headache, which belong to the spectrum of FMD-associated abnormalities but confers protection against atherosclerotic coronary artery disease, suggesting common underlying biology.[32–37]

Further genetic studies are needed in order to understand the role of genetic variation in the pathogenesis of FMD, and are underway. Knowledge of the genes underlying FMD will be needed for insight into the biology of FMD and to ultimately develop targeted therapeutic approaches. Further, knowing which genes are involved in FMD may be clinically useful to predict the risk of FMD in individuals, particularly in affected families. Ongoing research efforts are underway, including studies utilizing genome-wide association study methods (which will be best suited to identify common variants conferring risk to FMD under a model of complex genetic architecture) as well as whole exome sequencing and whole genome sequencing (which has the potential to identify rare and low frequency genetic variants with high impact).

CONSENSUS POINT: There are currently no genetic tests that are specific to FMD, and there is no justification for genetic testing of asymptomatic relatives of patients with FMD at this time. Pending future genetic developments, relatives of patients with FMD should only undergo clinical examination

Table 1. Clinical signs of renal artery FMD.

- Hypertensive patients < 30 years of age, especially women
- Accelerated, malignant, or grade 3 (> 180/110 mmHg) hypertension
- Drug-resistant hypertension (blood pressure target not achieved despite 3 drug-therapy at optimal doses including a diuretic)
- Unilateral small kidney without a causative urological abnormality
- Abdominal bruit in the absence of atherosclerotic disease or risk factors for atherosclerosis
- Suspected renal artery dissection/infarction
- Presence of FMD in at least one other vascular territory

Table adapted with slight modification by the writing committee from ref. 6.
FMD, fibromuscular dysplasia.

Table 2. Clinical signs/symptoms of cerebrovascular FMD.

Cardinal symptom or sign
- Severe and/or chronic migraine headaches, especially in the presence of other suggestive symptoms or signs[a]
- Pulsatile tinnitus ('whooshing' or 'swooshing' sound in the ears timed to heart beat)
- Cervical bruit on exam[b]
- Stroke, TIA[c], or amaurosis fugax
- Unilateral head/neck pain or focal neurologic findings (e.g. partial Horner's syndrome with ipsilateral ptosis and miosis) suggestive of a cervical artery dissection

Possible symptom
- Headaches (not chronic migraine or not migraine-type)
- Tinnitus (not pulsatile)
- Dizziness/light-headedness

[a]Chronic migraine is defined as headache occurring on 15 or more days/month for > 3 months, which on at least 8 days/month has the features of a migraine headache.[198]
[b]For FMD, cervical bruits are best heard high in the neck at the level of the angle of the mandible and with the bell of the stethoscope.
[c]Among patients with FMD, TIA-like events should be distinguished from migraine with aura by a dedicated neurological assessment.
FMD, fibromuscular dysplasia; TIA, transient ischemic attack.

and imaging-based evaluation of potentially affected arterial beds upon presentation with suggestive symptoms or signs of FMD (Tables 1 and 2).

Environmental factors

Tobacco smoking has been identified as a potential pathogenic factor associated with FMD. Case–control studies have demonstrated an association of both current smoking (OR, 2.5–4.05) and ever smoking (OR, 1.8–4.1) and renal FMD.[38–40] Among patients with multifocal FMD, current smokers experienced an earlier diagnosis of hypertension and FMD than non-smoking patients, and a greater likelihood of kidney asymmetry and further renal artery interventions.[40] In the US Registry for FMD, it was reported that patients with FMD with a history of smoking had a significantly higher rate of aneurysms than those who had never smoked and there was a trend toward increased prevalence of major vascular events in smokers.[41] Despite these data, smoking cannot be considered as a prerequisite for the development of FMD.[5,41]

Additional environmental factors, such as exposure to endogenous or exogenous female hormones, have also been associated with FMD, but the exact association remains unclear. Indeed, though the disease is far more prevalent in women than in men, no clear-cut causative link has been identified in those who have used oral contraceptives or other exogenous female hormones.[3,39,42] A recent case–control histology study suggested abnormal balance between estrogen and progesterone receptors in renal artery samples of patients who underwent surgery for renal FMD, characterized by intense progesterone receptor expression in the nuclei of smooth muscle cells which was not found in the samples of control patients.[43] These preliminary findings suggests that progesterone may also play a role in the pathogenesis of FMD, but this needs to be replicated in other studies.

Repeated stretching of the renal artery due to kidney mobility ('nephroptosis') has also been associated with FMD, but the exact nature of this relationship remains unclear.[44] However, available data do not support a major contribution of renal mobility as an important exposure for the development of FMD.[39] Mechanical factors may contribute to the formation of FMD in certain arterial locations, including the right more than left renal, mid to distal internal carotid, and external iliac arteries, but specific mechanisms are currently unknown.

Other potential pathogenic factors

In a small cohort of patients with multifocal FMD, secretion of transforming growth factor (TGF)-β1 and TGF-β2 by dermal fibroblast cell lines was increased compared with matched controls.[27] In this study, FMD patients also had elevated plasma levels of circulating TGF-β1 and TGF-β2 relative to matched controls. The potential involvement of TGF-β pathways in the pathogenesis of FMD is an area for future investigation.

It has recently been suggested that accumulation of *lysophosphatidylcholine (*lysoPC), a pro-inflammatory and pro-apoptotic lipid mediator, in the visceral arteries may reflect predisposition for the development of aneurysms among patients with FMD.[45] Differences in the distribution patterns of lipid molecules, including cholesterol esters and

lysoPC, between FMD-associated and atherosclerotic visceral artery aneurysms have been reported.[45]

Differential diagnosis of FMD and overlapping entities

An understanding of the unique clinical and imaging findings in patients with FMD is paramount to distinguishing FMD from other arterial diseases. The differential diagnosis of FMD is broad, and includes many other arterial pathologies as well as imaging artifacts.[46–58] The imaging diagnosis depends upon the finding of typical patterns of FMD (focal or multifocal lesions) as well as the presence of associated arterial findings (dissection, aneurysm, and tortuosity). Table 3 reviews key elements of the differential diagnosis of FMD.

Current status of US and European/International FMD registries

United States Registry for FMD

The US Registry for FMD began enrolling patients in January 2009 at seven clinical centers in the continental United States and has subsequently expanded to 13 actively enrolling clinical centers. The US Registry is funded by the FMD Society of America (FMDSA) with centralized data coordination in a secure online platform by the University of Michigan Cardiovascular Outcomes Research and Reporting Program (www.med.umich.edu/mcorrp/). As of February 2018, the US Registry has enrolled nearly 2000 patients and has had seven publications in peer-reviewed journals.[1,3,4,11,41,59,60] Some clinical centers in the US Registry enroll pediatric as well as adult FMD patients.

European/International FMD Registry

The European FMD Registry was launched on the occasion of the First National Meeting on FMD in Belgium (December 12, 2015), in parallel with the Belgian FMD initiative. Although no funding is currently available, the European Registry has been subsequently endorsed by the European Society of Hypertension (http://www.eshonline.org/). It has been adapted from the French FMD Registry (coordinator: P-F Plouin), created in 2010 to merge existing local FMD databases. It includes over 50 items covering demographic and clinical characteristics of FMD, family history, type, localization, associated complications, and interventions selected from the larger dataset used in the French ARCADIA Registry.[2,61] A flexible, secure online platform has been developed, which will allow for the addition of an indefinite number of new visits, imaging or vascular interventions.[62,63]

Since enrollment of the first patient in December 2015, the Registry includes 675 patients with FMD recruited in 30 centers from 17 different countries. Some clinical centers also enroll patients with SCAD. The Registry has become more international, with extensions using the same or similar datasets to national initiatives in Argentina (Sociedad Argentina de Hipertensión Arterial-República Argentina-Displasia Fibromuscular, SAHARA-DF), Japan, China (Chinese FMD initiative), and Tunisia. Besides new initiatives launched in the wake of the European initiative, the European FMD Registry also benefits from the contribution of pre-existing registries, such as ARCADIA-POL, currently including 220 patients from 32 centers in Poland, and initially inspired by the ARCADIA Registry but with its own specific objectives and research aims.[64] The latter are progressively incorporated in the European FMD Registry.

Comparison of US and European registries and objectives for the future

As can be seen in Tables 4 and 5, the US and European/International FMD registries share many similarities in structure and in clinical characteristics of patients enrolled. Although the assets of the newer European Registry include, among others, image archiving for systematic characterization of FMD subtype (multifocal/focal), inclusion of prevalent cases from smaller centers mostly focused on renal arteries or, less frequently, cerebrovascular arteries, probably accounts for the relatively low proportion of multivessel FMD compared to the US and ARCADIA registries.[2] Notably, in the subset of incident patients diagnosed after the creation of the European FMD Registry, differences with the US Registry and ARCADIA (e.g. in terms of age at diagnosis, estimated glomerular filtration rate, or proportion of patients undergoing interventions) tends to be much smaller (A Persu, personal communication, February 21, 2018). The writing committee anticipates that the current international consensus will be instrumental in harmonizing screening and imaging strategies within Europe and between Europe and the US.

The leadership of both registries are committed to make them even more compatible in the future in order to facilitate collaboration and merging of data on specific topics, to disseminate the current consensus in order to harmonize screening and management strategies within and between both registries, and to make efforts to expand the registries to more diverse populations of patients with FMD, including populations of non-white ethnicity, which are currently underrepresented in both registries.

Example of another initiative: the Australian FMD Registry

The Australian FMD Registry (ROKD-FMD) was established in 2015. This Registry is nested within the Australian Registry of Kidney Diseases (ROKD-FMD – http://rokd.org.au/), designed as a patient data aggregation platform to facilitate research, monitor clinical progression, and capture quality-of-care indices to assess patterns of care for Australian patients. Data are held in a secure platform at the Department of Epidemiology at Monash University in Melbourne, Australia. With the support of the FMD Association of Australasia, a very active patient advocacy group (http://www.fmdaa.org.au/), 41 patients have been enrolled as of February 2018.

Table 3. Differential diagnosis of FMD.

Disease	Key clinical and imaging features
Entities that may be confused with multifocal FMD	
Systemic arterial mediolysis (SAM)[46]	• Non-inflammatory, non-atherosclerotic disease • Manifests as spontaneous arterial dissection, rupture, occlusion, or aneurysm, most often in the abdominal visceral arteries • May be indistinct from multifocal FMD on angiographic imaging • Definitive diagnosis requires histopathological examination demonstrating vacuolar degeneration of the artery media
Arterial spasm Standing waves[57,58]	• Benign radiologic findings due to vasospasm such as those induced by ergotamine derivatives or sympathomimetic drugs or catheter-related vasospasm • Transient flow-related physiologic changes in the artery resulting in regular oscillations distinct from multifocal FMD (beading of varying size) • Neither entity requires further evaluation or follow-up when identified
Imaging artifacts	• Artifact on MRA resulting in areas of luminal irregularity due to patient motion • Streaking artifacts (such as from dental fillings) on CTA leading to the appearance of luminal irregularities • Artifacts may be mistaken for multifocal FMD
Entities that may be confused with focal FMD	
Atherosclerosis	• Patients with traditional cardiovascular risk factors: older age, hypertension, hyperlipidemia, tobacco use, obesity, diabetes, etc. • Predominantly affects the origin and proximal artery, branching points; can affect any arterial bed • Plaque with or without calcification may be visualized on CTA, MRA, or duplex ultrasound
Large vessel vasculitis (e.g. Takayasu, giant cell arteritis)[47,48]	• Clinical: fevers, weight loss, pain over the affected arteries; elevated inflammatory markers, anemia, thrombocytopenia • Imaging: focal or tubular stenosis and/or aneurysm of the aorta and branch vessels at the origin or proximal arterial segment; wall thickening/edema may be observed on CTA, MRA, or duplex ultrasound
Median arcuate ligament compression (Dunbar syndrome)[199]	• Compression of the celiac artery and neural ganglion by a fibrous band of the diaphragmatic crura, the median arcuate ligament • Clinical: often asymptomatic, but may cause chronic post-prandial epigastric pain with weight loss • Imaging: dynamic, focal stenosis at the celiac artery origin may be alleviated with deep inspiration or upright positioning; may also involve the superior mesenteric artery; post-stenotic dilatation may be present
Williams syndrome[49]	• Multisystem disorder affecting 1/10,000 live births • Clinical: 'Elfin facies' (broad forehead, upturned nose, pointed chin); developmental delay; hypercalcemia; garrulous personality; congenital heart defects • Imaging: supra-valvular aortic stenosis, mid-aortic syndrome, renal artery or pulmonary artery stenosis, coronary ostial stenosis or coronary artery dilation • Associated gene: *ELN*
Neurofibromatosis type 1[50]	• Autosomal dominant, multisystem disorder affecting 1/3000 live births • Clinical: freckling, café au lait spots, peripheral neurofibromas, optic gliomas, central nervous system neoplasms and soft tissue sarcomas, skeletal abnormalities, learning disabilities, renovascular hypertension • Imaging: renal artery stenosis, intracranial stenosis, including Moya-Moya (rare) • Associated gene: *NF1*
Alagille syndrome[51]	• Autosomal dominant, multisystem disorder affecting 1/70,000 births • Clinical: broad forehead, deep-set eyes and pointed chin; cholestasis, xanthomas; butterfly vertebrae; renal dysplasia; congenital heart defects • Imaging: intracranial artery aneurysm, carotid artery aneurysm, aortic aneurysm; intracranial stenosis, including moyamoya, stenosis of the aorta and renal arteries • Associated genes: *JAG1* and *NOTCH2*
Heritable connective tissue diseases associated with aneurysm and dissection	
Loeys–Dietz syndrome[52,53]	• Clinical: bifid uvula, craniofacial findings, e.g. craniosynostosis, hypertelorism, micrognathia (associated with more severe vascular disease) • Imaging: extreme arterial tortuosity; aneurysm, dissection • Associated genes: *TGFBR1, TGFBR2, SMAD3, TGFB2*
Ehlers–Danlos syndrome, type IV or vascular type[54–56]	• Clinical: acrogeria, easy bruising, translucent skin, tallipes equinovares (club-foot), family history of sudden death • Imaging: arterial dissection, aneurysm, and rupture of medium and large arteries, carotid-cavernous fistula; arteries may develop a 'string of beads' appearance on imaging during healing of a dissection • Clinical presentation and prognosis varies by molecular diagnosis • Gastrointestinal and uterine rupture may also occur • Associated gene: *COL3A1*

Table 3. (Continued)

Disease	Key clinical and imaging features
Spontaneous (primary) arterial dissection	• Young to middle-aged patients without traditional cardiovascular risk factors • Can be diagnosed after presentation with symptoms or incidentally on imaging • May occur in many arterial beds, including cervical (carotid, vertebral), coronary, and renal or visceral artery dissection, as well as others • No evidence of vasculitis, FMD focal or multifocal lesions, or heritable connective tissue disease • Patients may have family history of aneurysm, dissection or sudden death • May be associated with other vascular findings, including arterial tortuosity or other areas of arterial dissection

CTA, computed tomographic angiography; FMD, fibromuscular dysplasia; MRA, magnetic resonance angiography.

Table 4. Study design and overall characteristics of adult patients enrolled in the United States and European/International FMD registries.

	US Registry for FMD	European/International Registry
First patient included	January 2009	December 2015
No. of patients analyzed (no. of patients in Registry)	1885 (1910) as of 2.12.2018	609 (675) as of 1.10.2018
Retrospective/prospective data collection	Both	Both
Association with archived images	No	Since October 2017
Association with DNA/biobank	No	Yes
No. of countries	1	17[a]
No. of actively enrolling centers	13	30
Patients with follow-up (%)	1240 (65.8)	123 (20.2)
Median duration of follow-up, months (median, IQR)	29.7 (12.9–55.0)	12.6 (7.6–29.5)
Age at enrollment, years (mean ± SD, min–max)	56.1 ± 12.3, 18–90	51.2 ± 15.1, 18–94
Age at diagnosis, years (mean ± SD, min–max)	53.3 ± 12.8, 5–89	45.8 ± 15.8, 4–84
Females (%)	1785 (94.7)	508 (83.3)
Ethnicity (%)		
• White	1615/1768 (91.3)	498 (81.8)
• African descent	89/1768 (5.0)	7 (1.1)
• Maghreb-Middle East	–	20 (3.3)
• Asian	6/1768 (0.3)	44 (7.2)
• Hispanic	46/1768 (2.6)	40 (6.6)[b]
• Native American	2/1768 (0.1)	–
• Other	10/1768 (0.6)	–
Systolic blood pressure at enrollment, mmHg (mean ± SD)	131.5 ± 19.7	138.3 ± 23.0
Diastolic blood pressure at enrollment, mmHg (mean ± SD)	74.7 ± 12.0	83.7 ± 14.3
Hypertension (%)	1253/1862 (67.3)	449 (73.7)
Age at hypertension diagnosis, years (mean ± SD)	44.8 ± 14.0	36.5 ± 14.8
No. of antihypertensive drugs at enrollment (mean ± SD, median, IQR)	1.9 ± 1.0, 2, 1–3	2.4 ± 1.3, 2, 1–3
Headache (%)	1274/1837 (69.4)	Pending
Pulsatile tinnitus (%)	374/1661 (22.5)	Pending
Stroke (%)	185/1828 (10.1)	46/601 (7.7)
TIA (%)	222/1802 (12.3)	21/601 (3.5)
Subarachnoid hemorrhage (%)	40/1778 (2.2)	21/601 (3.5)
Current smokers (%)	193/1814 (10.6)	125/594 (21.0)
Ever smokers (%)	607/1814 (33.5)	Pending
Post-menopausal women (%)	1045/1533 (68.2)	Pending
Body mass index (mean ± SD)	25.9 ± 6.0	24.6 ± 4.9
Serum creatinine, mg/dL (mean ± SD)	0.8 ± 0.2	0.9 ± 0.5
Estimated GFR CKD-EPI, mL/min/1.73 m^2 (mean ± SD)	83.6 ± 20.3	91.2 ± 37.5

If not specified, the denominator is the total number of patients analyzed.
[a]Including three extra-European countries: Argentina, Japan, and Tunisia; China pending.
[b]Patients from Argentina.
CKD-EPI, Chronic Kidney Disease Epidemiology Collaboration; GFR, glomerular filtration rate; TIA, transient ischemic attack.

Table 5. Vascular manifestations and type of FMD of adult patients enrolled in the United States and European/International registries.

	US Registry for FMD $n = 1885$	European/International Registry $n = 609$
Multifocal FMD (%)[a]	1433 (76.0)	438 (71.9)
Focal FMD (%)	45 (2.4)	171 (28.1)
Cannot determine/missing/other (%)[b]	407 (21.5)	–
Coexisting lesions of atherosclerosis	–	126/601 (21.0)
Multivessel FMD (%)[c]	1038 (55.1)	190 (31.2)
– 2 sites (%)	591 (31.4)	126 (20.7)
– 3 sites (%)	285 (15.1)	49 (8.0)
– 4 sites (%)	124 (6.6)	14 (2.3)
– 5 sites (%)	28 (1.5)	1 (0.2)
– 6 sites (%)	10 (0.5)	–
% of patients with imaging of each vascular bed		
Renal	1628 (86.4)	554 (91.0)
Cerebrovascular, including intracranial	1681 (89.2)	370 (60.8)
Mesenteric	1118 (59.3)	441 (72.4)
Lower extremity	402 (21.3)	188 (30.9)
Upper extremity	159 (8.4)	–
Aorta	938 (49.8)	211 (34.6)
Coronary arteries	195 (10.3)	17 (2.8)
% of patients with imaging of each vascular bed in whom lesions were found		
Renal	1076/1628 (66.1)	509/554 (91.9)
Cerebrovascular	1352/1681 (80.4)	217/370 (58.6)
– Extracranial carotid	1279/1658 (77.1)	176/370 (47.6)
– Intracranial carotid	197/1173 (16.8)	–
– Vertebral	495/1342 (36.9)	65/370 (17.6)
– Other	–	21/370 (5.7)
Mesenteric	169/1118 (15.1)	92/441 (20.9)
Lower extremity	181/402 (45.0)	47/188 (25.0)
Upper extremity	37/159 (23.3)	11/370 (3.0)
Aorta[d]	34/938 (3.6)	10/211 (4.7)
Coronary arteries[e]	94/195 (48.2)	4/17 (23.5)
At least 1 aneurysm in any vascular bed (%)	406/1790 (22.7)	122 (20.0)
Aortic aneurysm (%)	43/406 (10.6)	Pending
At least 1 dissection in any vascular bed (%)	514/1828 (28.1)	21 (3.4)
At least 1 vascular bed treated with procedure (%)	690 (36.6)	338 (55.5)
Family history of FMD (%)	89/1644 (5.4)	17/603 (2.8)

If not specified, the denominator is the total number of patients analyzed.
[a]The small proportion of patients with both multifocal and focal FMD was labelled as having multifocal FMD.
[b]The US Registry does not currently include a centralized imaging review for type of FMD. Reported data are based on coding of variable 'type of FMD'. A significant percentage of these patients have multifocal FMD based on coding of beaded arterial lesions in at least one vascular bed on arterial imaging studies (J Froehlich, H Gornik, J Olin, personal communication, February 12, 2018).
[c]Not all patients underwent brain to pelvis imaging to assess for multivessel FMD.
[d]Aortic involvement primarily manifests as aortic aneurysm with FMD lesions in other vascular beds.
[e]May include atherosclerotic coronary lesions, coronary artery tortuosity, and SCAD.
FMD, fibromuscular dysplasia; SCAD, spontaneous coronary artery dissection.

Imaging and diagnosis of FMD

Renal FMD

The prevalence of renal FMD in the general population is unknown because this disease is often clinically silent or discovered incidentally. However, studies from living kidney donor candidates and other clinical series indicate a prevalence of renal FMD of 3–4%, and the prevalence of incidental renal FMD among patients with renovascular hypertension enrolled in the Cardiovascular Outcomes in Renal Atherosclerotic Lesions (CORAL) trial was 5.8%.[29,65] Among subjects with FMD in the US and ARCADIA registries, the renal arteries were involved in approximately 75% of patients.[2,4] Based upon Registry data, the typical clinical phenotype of renal FMD is a middle-aged, white woman with hypertension, as well as a family history of hypertension, and up to 90% of these women have a multifocal type of FMD.[2,4] Focal FMD is usually discovered before 30 years of age and often with blood pressure values on average higher than those observed among patients with the multifocal form.[10] There is a more balanced sex distribution among patients with focal compared to multifocal FMD.[10,60] Hypertension is, by far, the

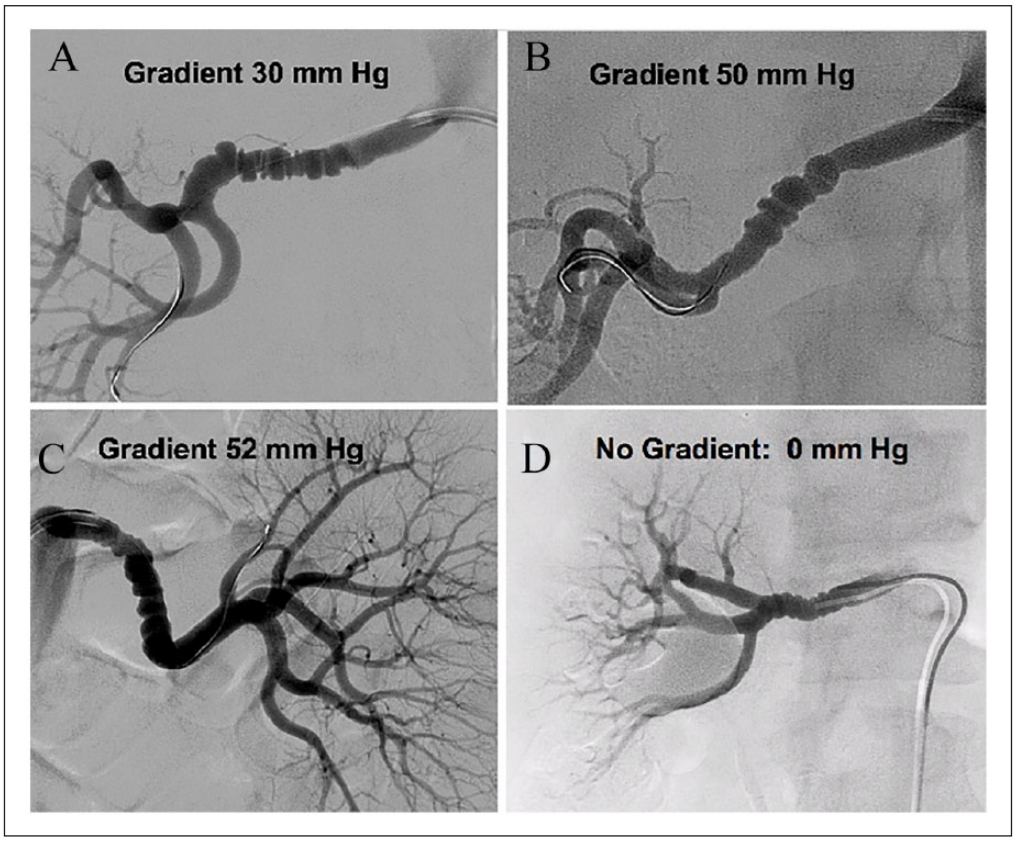

Figure 2. Measurement of translesional pressure gradients in renal artery FMD (A–D). Despite the appearance of multifocal FMD in all renal arteries, pressure gradients were highly variable, supporting the consensus that visual inspection alone is not adequate to determine the hemodynamic significance of multifocal renal FMD.
FMD, fibromuscular dysplasia.

most frequent presenting symptom among patients with renal FMD, whereas headache (especially migraine), pulsatile tinnitus, transient ischemic attack (TIA) or stroke may be the hallmark of cerebrovascular FMD (see below).

The proposed criteria to proceed to imaging assessment for renal FMD (Table 1) have been adapted with slight modification from the 2014 European FMD consensus.

Diagnostic approach to renal FMD. When a clinical suspicion of renal FMD has arisen, as outlined above (Table 1), the first step to confirm (or exclude) the diagnosis should be to perform a non-invasive imaging study. It is the consensus of the writing committee that computed tomographic angiography (CTA) is the initial test of choice for suspected FMD, but contrast-enhanced magnetic resonance angiography (MRA) is an option if CTA is contraindicated. CTA is preferable to MRA for diagnosis of FMD because of better spatial resolution. Moreover, CTA better visualizes small calcifications, thereby providing a more accurate discrimination of FMD from atherosclerotic renal artery stenosis. Although there are small cases series that have explored the diagnostic accuracy of CTA or MRA compared to angiography for FMD, it should be stressed that most studies of the diagnostic accuracy of various imaging techniques have been done in patients with atherosclerotic renal artery stenosis.[66–68] It is the consensus of the writing committee that duplex ultrasound as the first diagnostic test for renal FMD should only be considered in specialized centers with extensive experience in duplex ultrasound for evaluation of FMD.

When the results of CTA or MRA confirm the diagnosis of FMD, or when a high clinical suspicion persists despite negative findings on CTA or MRA, proceeding to catheter-based angiography may be considered. Although catheter-based angiography is the gold standard for imaging the location and morphology of FMD, it is indicated only when its findings are expected to impact patient management. In patients with renal artery FMD, particularly of the multifocal type, imaging alone does not allow for determining the severity and hemodynamic significance of renal artery stenosis (Figure 2). Renal blood flow and renin secretion are often normal, and because FMD is often bilateral, there may be no lateralization on renal vein renin sampling. Therefore, translesional pressure gradient measurement is recommended in order to assess the hemodynamic significance of stenosis, particularly in multifocal FMD, as well as post-angioplasty in both focal and multifocal FMD to ensure the pressure gradient has been obliterated. In experienced centers, the procedure may be combined with intravascular ultrasound (IVUS) or optical coherence tomography (OCT). A proposed consensus protocol for catheter-based angiography in renal FMD is detailed in Table 6 and discussed below.

CONSENSUS POINT: An imaging-based evaluation for renal artery and/or cerebrovascular FMD should

Table 6. Consensus protocol for catheter-based angiography and PTA in patients with renal artery FMD.

1. Flush aortogram (if prior cross-sectional imaging with CTA or MRA had not been previously performed) to look for all renal arteries and clearly profile the ostia of the renal arteries (with oblique views) prior to selective catheterization.
2. Selective renal arteriography, using multiple views, to visualize the entire renal vasculature, including for branch vessel involvement, kidney size, parenchymal perfusion, and assessment for renal artery aneurysm/dissection.
3. A simultaneous, unstimulated, translesional pressure gradient (between the distal renal artery and the aorta) should be measured, ideally with a pressure wire.[a] If a pressure wire is not available, a small diameter end-hole catheter may be used for a pull-back pressure. In experienced centers, IVUS or OCT may also help to identify the severity of stenosis in patients with multifocal FMD.
4. A pressure gradient threshold of 10% of the mean (aortic) pressure can be used to decide whether to perform balloon angioplasty (i.e. Pd/Pa < 0.90).[137] These parameters are extrapolated from the study of patients with atherosclerotic renal artery stenosis and have not been validated in patients with FMD.
5. For angioplasty, the initial balloon diameter used should be based upon the diameter of the distal normal renal artery using a calibrated catheter and quantitative vascular angiography software, IVUS, or OCT. The balloon diameter size should be incrementally increased by 0.5 mm until the translesional gradient is resolved or until there is a $<$ 10% mean translesional gradient. Angioplasty should be aborted if the patient experiences pain during balloon inflation or if a complication occurs.
6. Renal artery stenting is generally not indicated in the setting of FMD and is limited for bail-out use to treat complications related to angioplasty (dissection, pseudoaneurysm, or rupture), in some cases of primary renal artery dissection, or for the treatment of a renal artery aneurysm.
7. At the end of the procedure, final angiograms are obtained using the same catheter and orthogonal views that were used for baseline angiography to assess for potential complications (renal artery dissection, pseudoaneurysm, rupture, renal emboli, or infarction).
8. This procedure can be performed on an outpatient basis most of the time. However, some patients may require monitoring overnight in the hospital.

[a]For patients with focal FMD, and to avoid trauma due to catheter manipulation, measurement of a pre-treatment pressure gradient is not needed if the stenosis is severe by visual inspection on selective angiography; however, measurement of post-treatment pressure gradient assessment is essential to be certain the lesion has been adequately treated.
CTA, computed tomographic angiography; FMD, fibromuscular dysplasia; IVUS, intravascular ultrasound; MRA, magnetic resonance angiography; OCT, optical coherence tomography; PTA, percutaneous angioplasty.

be considered in the presence of symptoms or signs listed in Tables 1 and 2.

CONSENSUS POINT: For patients with suspected renal artery FMD, CTA is the initial imaging modality of choice. Contrast-enhanced MRA is an alternative to CTA when CTA is contraindicated. Duplex ultrasound may be used as the first diagnostic procedure for renal FMD only in specialized centers with extensive expertise in duplex ultrasound for FMD.

Cerebrovascular FMD

Historic estimates of cerebrovascular FMD report a lower frequency of involvement as compared to renal artery FMD; however, contemporary reports that include systematic imaging of arterial beds beyond the initial site of diagnosis have revealed similar rates of cervical artery and renal artery disease.[2,4,69,70] In cases of CeAD (carotid or vertebral) related to FMD, focal neurologic findings with or without associated neck, face, or head pain may occur.[1,71] Prior publications report that the prevalence of FMD in individuals with CeAD may be as high as 15–20%, although vascular beds beyond the cerebrovascular circulation were not evaluated for FMD in the majority of these cases.[71–73] In the US Registry for FMD, 26% of subjects experienced an arterial dissection, most often in the carotid or vertebral arteries.[1] In the French ARCADIA Registry, CeAD was observed in 20/165 (12%) patients who presented with symptomatic cerebrovascular FMD.[2] Most often, symptoms related to cerebrovascular FMD are non-specific and may include headaches in ~50% of patients (especially confirmed and self-reported migraine type), pulsatile tinnitus (a 'whooshing noise' in the ears timed to the heart beat), and dizziness or light-headedness.[2,4] Notably, 5.6% of patients in the US Registry presented with no symptoms and FMD was identified incidentally on imaging.[4]

The lack of specific symptoms in FMD presents a challenge, as up to 25% of women in the general population may experience migraine headaches in their lifetime and only a subset will have FMD identified on a cerebrovascular imaging exam. The American Academy of Neurology guidelines advocate for neuroimaging for patients with migraine who have neurologic findings on physical examination or a change in the quality or severity of headache, but this approach would potentially miss a sizeable portion of patients with FMD because this neuroimaging does not necessarily include the cervical arteries.[74] The diagnosis of FMD should be considered and imaging pursued in patients with a cardinal symptom or sign of cervical artery FMD (Table 2).[5,6]

Diagnostic approach to cerebrovascular FMD. There are inadequate data to recommend one imaging modality over another for the diagnosis of cerebrovascular FMD. Catheter-based angiography remains the diagnostic gold standard; however, in most centers, this modality has been replaced by CTA or contrast-enhanced MRA as the initial imaging modality. Catheter-based angiography is typically reserved for complicated cases that may require intervention, such as the repair of an aneurysm or pseudoaneurysm related to dissection, or in rare cases of hemispheric neurological symptoms despite medical therapy associated with severe stenotic lesions. In high-volume centers with experience in vascular duplex

ultrasonography for the evaluation of carotid FMD, it is reasonable to start with a carotid duplex exam, although this modality is inadequate to assess the vertebral and intracranial arteries for FMD. To date, there are no validated criteria for the diagnosis of carotid FMD by duplex ultrasound. However, characteristic findings may be identified that support the diagnosis, including turbulence, elevated velocities, and tortuosity in the mid-distal portion of the ICA, an area which is typically unaffected by atherosclerosis.[5,6,12] This is in contrast to atherosclerosis, which typically affects the origin/proximal vessel (see Table 3). Carotid duplex may also be useful for interval follow-up and surveillance of patients with carotid artery FMD.[5,6] Although catheter-based angiography remains the diagnostic gold standard, in most cases this modality has been replaced by non-invasive CTA or MRA.

Unruptured aneurysm is the primary manifestation of intracranial FMD. For patients with confirmed FMD in any location, brain imaging with CTA or MRA should be performed to evaluate for intracranial aneurysm, as the prevalence of intracranial aneurysms is significantly increased compared to the general population.[1,5,6] In the US Registry, 12.9% of women had an intracranial aneurysm on imaging and a higher percentage of these were in a high-risk location (posterior circulation) and of larger size than comparable studies that screened the general population.[11] More than one-half of patients with intracranial aneurysm had multiple aneurysms.[11]

Carotid bulb diaphragm. An entity named 'carotid web' or 'carotid bulb diaphragm' has been classified as atypical FMD of the carotid bulb by some authors and has been described predominantly in black/Afro-Caribbean patients.[75–77] Although diaphragms were mainly reported in the carotid bulb, they have also been described in the ostium and V3 segment of the vertebral artery.[78,79] These diaphragms are endoluminal webs or spurs that can be visualized as linear defects on CTA or MRA. This entity seems to be associated with a high risk of ischemic stroke, likely via an embolic mechanism, which may justify carotid stenting or endarterectomy in the setting of recurrent ischemic events despite medical management.[76,77,80] Few cases in published series had pathologic specimens available for histologic review. Those that did describe 'a loose matrix of edematous tissue and sparse spindle cells, especially in the outgrowth, resulting in intimal hyperplasia', which is consistent with historic reports of this finding.[81–83] However, it is not clear that this entity is consistent with classic intimal FMD, and there are no reported analogous findings in any other arterial bed to support a diagnosis of FMD.[84] Additionally, histologic evaluation of some of these lesions represents atheroma.[85] Thus, interpretation of these lesions with imaging alone should be approached with caution and it seems that this entity is likely distinct from the clinical syndrome of FMD discussed in this document.

CONSENSUS POINT: There are inadequate data to recommend one imaging modality over another for assessment of suspected cerebrovascular FMD. At most centers, CTA or contrast-enhanced MRA is the initial diagnostic modality of choice, as determined by local resources and experience. In high-volume centers with extensive expertise in duplex ultrasound for FMD, this modality may be used for initial assessment of suspected carotid artery FMD, though carotid duplex is not adequate to assess the distal internal carotid, vertebral, or intracranial arteries.

CONSENSUS POINT: Regardless of initial site(s) of vascular bed involvement, patients with FMD should undergo at least one-time assessment for intracranial aneurysm with brain CTA or MRA. Whether brain CTA or MRA should be repeated after a period of time for patients without detected aneurysm on the initial study is unknown.

FMD in other locations – visceral, iliac, brachial artery FMD

Beyond the renal and cervical arteries, FMD can be present in any arterial bed, with more common additional locations being the visceral, lower, and upper extremity arteries (Figure 3).[4] Involvement of these other arterial beds generally occurs among patients with multivessel FMD.

Visceral artery FMD. Visceral artery FMD includes the celiac axis and hepatic and splenic arteries, and the superior and inferior mesenteric arteries. The US Registry and the French ARCADIA Registry reported visceral artery involvement in 19.3% (95/493) and 17.5% (82/469) of patients who underwent imaging studies.[2,86] The Polish ARCADIA-POL Registry reported mesenteric involvement in 13.2% (19/144) and splenic artery involvement in 10.4% (15/144) of patients.[64] Patients with visceral FMD are more likely to have aneurysms or dissections compared to those without visceral FMD (41.2% and 35.6% vs 19.7% and 20.6%, respectively).[86] In the US Registry, visceral locations accounted for 13.0% and 5.9% of all aneurysms and dissections, respectively.[1] In the Polish ARCADIA-POL Registry, aneurysms in the splenic arteries were found in 7.8% of patients.[64] Visceral artery FMD can present as postprandial flank or abdominal pain, mesenteric ischemia, aneurysms, dissections, or with an abdominal bruit.[4] Visceral artery FMD may also be an incidental finding on an imaging study obtained for other purposes. Cases of FMD involving the hepatic artery and associated with spontaneous dissection presenting with acute abdominal pain and shock have been reported.[87,88]

Iliac and lower extremity FMD. Lower extremity FMD is most commonly multifocal and bilateral, and typically involves the external iliac arteries; however, it has also been reported in common iliac, internal iliac, common femoral, deep femoral, superficial femoral, and popliteal arteries.[2,64,89,90] In the French ARCADIA and Polish ARCADIA-POL registries, FMD involving the iliac arteries was present in 14.7% (69/469) and 7.6% (11/144) of patients, respectively.[2,64] In a study from the Cleveland

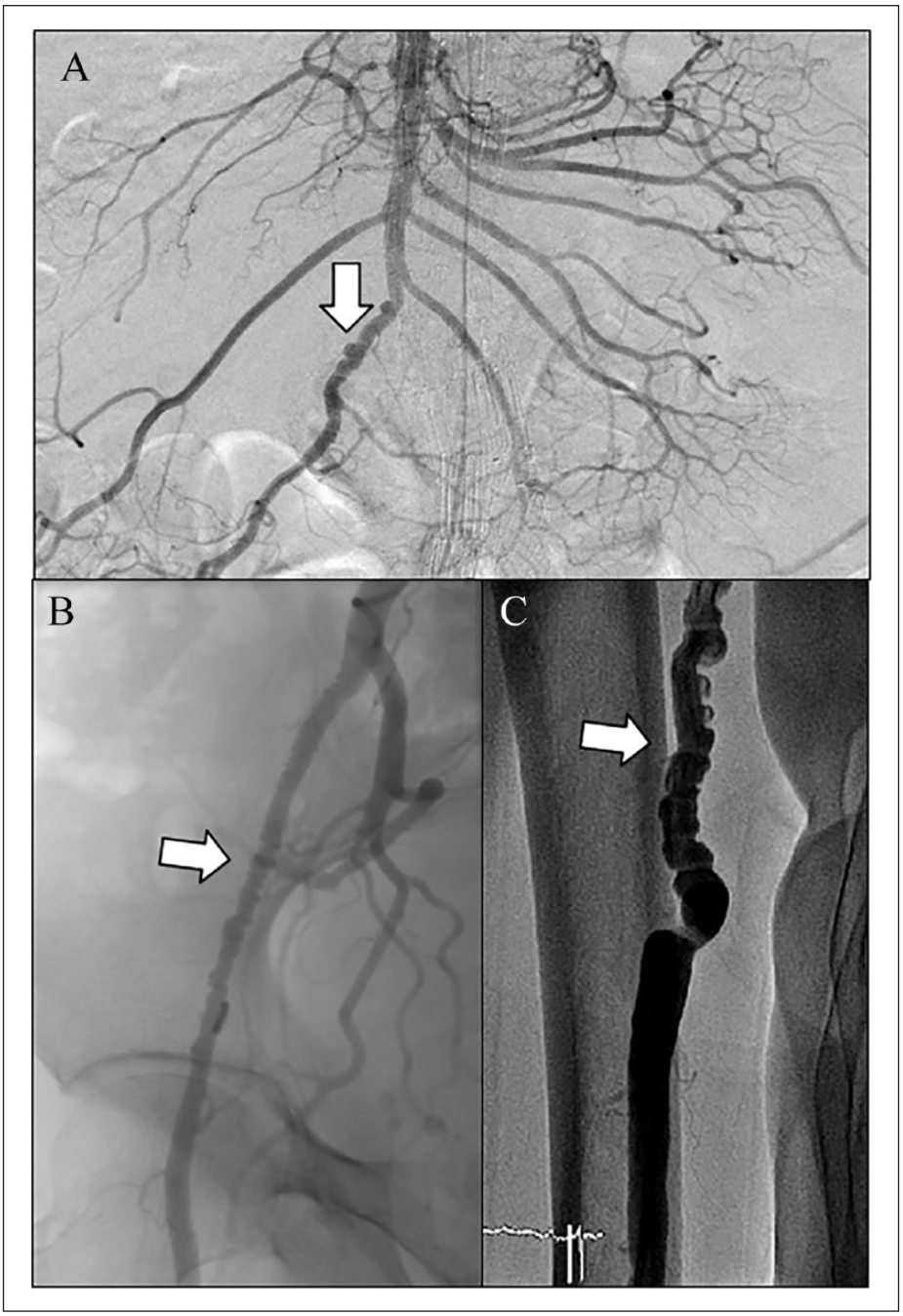

Figure 3. Angiographic images of multifocal FMD (arrows) from the superior mesenteric (A), external iliac (B), and brachial arteries (C). FMD, fibromuscular dysplasia.

Clinic where 100 of 449 FMD patients had lower extremity imaging, generally for symptoms or signs (femoral bruit) of involvement, 62% had FMD in the lower extremity arteries.[89] Potential symptoms include claudication, foot or toe ischemia, and atypical leg symptoms; dissections and aneurysms may occur. The majority of patients with lower extremity involvement are asymptomatic and may be diagnosed by femoral bruit noted on physical examination or incidentally on imaging studies. Standing waves on catheter-based angiography can be misdiagnosed as lower extremity FMD and are an important differential diagnosis (Table 3). Standing waves are a benign phenomenon that may appear with regularly shaped 'string of beads', but do not have the same clinical implications as FMD.[57]

Upper extremity FMD. Upper extremity FMD has been reported in 15.9% (10/63) of patients who underwent upper extremity imaging in the US Registry.[4] It typically involves the brachial artery, although it has been reported in the subclavian, axillary, radial, and ulnar arteries.[4,91] It is most commonly of the multifocal type with the majority of patients having both asymptomatic and bilateral involvement.[91] Symptoms of upper extremity FMD may include finger or hand ischemia (rest pain, discoloration, ulceration or gangrene) from thromboembolism or dissection and hand or arm claudication.[91–94] Other manifestations include Raynaud's phenomenon, paresthesia, and rarely aneurysms.[91–94] Brachial bruit and discrepant arm blood pressures are frequently identified on physical exam when brachial FMD is present.[91]

Diagnostic approach and imaging for FMD at other locations. To date, no studies have compared the accuracy of diagnostic imaging modalities for visceral, lower, or upper extremity FMD. In experienced centers, duplex ultrasound can be used to identify FMD by demonstrating stenosis, marked turbulence in both color Doppler and spectral Doppler waveforms, and potential for delayed up-stroke (parvus-et-tardus waveform) in arterial segments distal to areas of stenosis.[4] Findings must be differentiated from atherosclerotic disease based on location of the lesion and absence of plaque. In some cases, color power angio and grayscale imaging may show a beaded arterial appearance and intraluminal webs. Duplex ultrasound is likely to have the greatest diagnostic value in assessing the readily accessible brachial arteries as it may inadequately visualize the external iliac and visceral arteries.[4,6] Although duplex can be a good initial diagnostic tool in experienced centers, it is operator dependent and less sensitive than CTA, MRA, or catheter-based angiography for the diagnosis of FMD at other locations. Hence, if there is strong clinical suspicion of FMD, then further testing with other forms of imaging is recommended even if duplex evaluation is unremarkable or non-diagnostic. Though seldom required for diagnostic purposes alone, catheter-based angiography remains the gold standard for diagnosis of FMD, including for involvement of the visceral and extremity arteries.

Systemic nature of FMD

In the ARCADIA Registry, systematic imaging of 469 patients presenting either as renal or cerebrovascular FMD led to the identification of focal or multifocal FMD lesions in at least one other vascular bed in 48% of patients, and of other vascular lesions such as aneurysms or dissections in another 18%, leading to an overall prevalence of 66.3% of multivessel FMD as defined in the current consensus.[2] These findings are consistent with those of the US Registry, in which more than 50% of patients now have multivessel involvement, though in the latter systematic imaging was not undertaken in all patients (Table 5). Along the same lines, in a single-center retrospective series of 113 consecutive patients with FMD who underwent a dedicated chest to pelvis CTA protocol, new findings were identified in a significant percentage of patients: 55 (48.7%) new FMD lesions, 21 (18.6%) new aneurysms, and three (2.7%) new arterial dissections.[69]

Although in the ARCADIA study, the probability of having cerebrovascular FMD was higher in patients with bilateral rather than unilateral renal FMD (OR, 1.88; 95% CI, 0.99–3.57) and, not unexpectedly, the probability of having renal FMD was higher in patients with cerebrovascular FMD with hypertension (OR, 3.4; 95% CI, 1.99–6.15), these correlations are not strong enough to restrict comprehensive vascular imaging to specific subgroups of patients with FMD.[2] Therefore, and also in view of the availability of new CTA protocols allowing for high-quality image acquisition with decreased irradiation and contrast exposure, the sequential imaging approach recommended in previous consensus documents can be abandoned in favor of brain to pelvis cross-sectional imaging by CTA or contrast-enhanced MRA in all patients with FMD.[4,6,61,69,95] At present, coronary artery imaging for potential manifestations of FMD is not recommended in the absence of symptoms (see SCAD and coronary FMD below).

CONSENSUS POINT: Regardless of the initial site of vascular bed involvement, patients with FMD should undergo imaging of all vessels from brain to pelvis, at least once and usually with CTA or contrast-enhanced MRA, to identify other areas of FMD, as well as to screen for occult aneurysms and dissections.

Management of FMD

Medical therapy

Antiplatelet therapy. There are no trials assessing the utility of medical therapy in FMD or prospectively comparing medical therapy to intervention in this population. As patients with FMD may present with thrombotic and thromboembolic events, even in the absence of dissection or aneurysm, antiplatelet agents are reasonable for both symptomatic and asymptomatic FMD.[4,59,91] This practice is also supported by FMD pathophysiology, especially that of multifocal FMD, as intra-arterial webs and areas of dilatation may serve as a nidus for platelet aggregation.[1] Nevertheless, one should keep in mind that there are no placebo-controlled studies of antiplatelet therapy for FMD and there are no data to support one agent over the other. Accordingly, the potential benefits versus risks of antiplatelet therapy should be weighed on an individual basis, including factors such as prior thromboembolic events, arterial dissection, or revascularization procedures (each of which would support antiplatelet use), as well as risk factors for bleeding (e.g. prior history of subarachnoid hemorrhage or other bleeding events, large intracranial aneurysm). In the US Registry, 72.9% of patients were prescribed antiplatelet therapy, with aspirin being the most commonly prescribed agent.[59] Older age, concomitant coronary artery disease, prior vascular intervention, and isolated cerebrovascular FMD were factors associated with higher rates of antiplatelet use.[59]

CONSENSUS POINT: In the absence of contraindication, antiplatelet therapy (i.e. aspirin 75–100 mg daily) is reasonable for patients with FMD to prevent thrombotic and thromboembolic complications.

Treatment of hypertension. Because the ideal blood pressure target in patients with FMD is unknown, it is reasonable to follow general recommendations, such as those of the 2017 American College of Cardiology/American Heart Association multisocietal Guideline for the Prevention, Detection, Evaluation, and Management of High Blood Pressure in Adults and the recently published guidelines of the European Society of Cardiology and European Society of Hypertension.[96,97] The majority of patients with FMD receive antihypertensive medications.[59] There are several potential justifications for this practice. First, hypertension is common among patients with FMD, either due to essential or renovascular hypertension associated with renal artery involvement.[4] Although all antihypertensive medication can

be prescribed in renovascular hypertension, angiotensin-converting enzyme (ACE)-inhibitors or angiotensin receptor blockers (ARB) have been recommended in this setting.[97,98] Following SCAD, beta-blockers may have a protective effect.[99] Control of hypertension is particularly important for patients with FMD who have intracranial aneurysms, as well as aneurysms at other locations. Certain antihypertensive medications (i.e. beta-blockers, calcium channel blockers, ARBs) may also be effective as preventive therapies for migraine.

Management of headache and pulsatile tinnitus. Medical therapy for the care of the patient with FMD should also address common symptoms of headache and pulsatile tinnitus that may have an impact on quality of life.[4] In the US Registry, significant headache was reported in 67.5% of patients, with more than one-half of patients reporting headaches at least weekly.[100] Although migraines are the most common headache type among patients with FMD (38% of patients in the US Registry; 28% in ARCADIA), headache may also be related to uncontrolled hypertension or CeAD.[2,4,101] Migraines may occur in patients with FMD even in the absence of cerebrovascular involvement. As for all patients with migraine, the approach to migraine in patients with FMD may include lifestyle modification to avoid triggering factors, preventive therapies, and medications to abort migraines. Although there are no specific studies of migraine therapies for patients with FMD, particular caution is advised in prescribing tryptans, ergots, and other vasoconstrictive agents. This is especially important among those patients with a prior history of CeAD or SCAD, in whom these agents may be contraindicated.[101]

As discussed above, pulsatile tinnitus has recently been recognized as a common manifestation of cerebrovascular FMD, reported as a presenting symptom in 32% of all patients in the US Registry.[102] Patients may respond to reassurance and education, but other approaches including sound or cognitive behavioral therapy may be helpful for some patients with more severe symptoms, though experience is limited for management of pulsatile (compared to non-pulsatile) tinnitus.[103–105] Consultation with audiology and otolaryngology may be helpful to evaluate hearing and to assess for other causes of pulsatile tinnitus beyond FMD.

Additional considerations. Statins, which are routinely prescribed for atherosclerotic cardiovascular disease, are not recommended routinely for patients with FMD in the absence of another indication, such as hyperlipidemia or concomitant atherosclerosis.[106–108]

Smoking cessation has been shown to have many health-related benefits in the general population.[109] Patients with FMD who smoke have been shown to have a higher prevalence of aneurysms and more adverse events, including the need for vascular procedures.[40,41] Smoking cessation should be strongly encouraged for all patients with FMD who continue to smoke.

FMD is predominantly a disease of women, and concern has been raised for exogenous hormone therapies in these patients (e.g. oral contraceptive pills or hormone replacement therapy). To date, however, these concerns remain theoretical, as no data exist to support the safety or harm associated with exogenous female hormones in FMD.

Finally, patients with FMD often require guidance regarding physical limitations, especially if a prior arterial dissection has occurred. There are no data to inform on such guidance, however, and the risk of adverse arterial events differs for each patient. Some activities are known to be associated with CeAD in the general population, including chiropractic neck manipulation and roller coaster rides.[110,111] These are best avoided. Other activities that include prolonged neck extension or severe neck traction, weight training or heavy lifting, and physical blunt-force contact (e.g. martial arts) should be addressed on a case by case basis.

Management of arterial dissection and aneurysm in patients with FMD

Cervical artery dissection and intracranial aneurysm

Cervical artery dissection (CeAD). In the absence of data from randomized trials specific to patients with FMD, management of CeAD (i.e. carotid or vertebral) among patients with FMD is similar to that of patients without FMD.[112,113] In acute stroke due to CeAD, both intravenous thrombolysis and mechanical thrombectomy can be used in eligible patients, although there is no specific data regarding the benefit of these therapies in this situation.[114,115] In case of carotid artery occlusion or severe carotid stenting due to CeAD, acute carotid artery stenting is sometimes required before mechanical thrombectomy can be performed. As the vast majority of patients with CeAD will not require thrombolysis, antithrombotic treatment is used in order to prevent recurrent ischemic events. The American Heart Association/American Stroke Association guidelines recommend treatment with either an anticoagulant or an antiplatelet agent for at least 3–6 months in patients with CeAD associated with ischemic stroke or TIA, and this position has been supported by the results of the CADISS trial.[113,116] The consensus of the writing committee is that this recommendation also applies to patients with CeAD in the setting of underlying FMD. There are very limited data on the use of direct oral anticoagulants in the management of CeAD.[117] Beyond the initial 3–6 months, antiplatelet therapy is generally continued long term. Endovascular therapy (e.g. carotid artery stenting) is typically restricted to cases with persistent cerebrovascular ischemia despite optimal medical therapy.[118,119] Additionally, pseudoaneurysms resulting from a dissection are at low risk for ischemic events or rupture and rarely require endovascular treatment.[120,121] If endovascular intervention is indicated, careful attention should be made to avoid iatrogenic vascular injury during groin access or guide catheter placement. However, it is unknown whether the existence of FMD increases the risk of iatrogenic dissection or post-stenting pseudoaneurysm development.

Intracranial aneurysm. As discussed above, the writing committee recommends screening patients with FMD for

unruptured intracranial aneurysm given the significant prevalence in this population, although the management of this entity remains controversial. The mean annual risk of rupture of unruptured intracranial aneurysm is < 1% in the general population, but it is unknown whether FMD is associated with an increased risk of rupture.[122] Management choice is influenced by the life expectancy of the patient, the estimated risk of rupture, the risk of complications of preventive treatment, and the level of anxiety caused by the awareness of having an aneurysm.[122] The risk of rupture depends on many factors, including aneurysm-related factors (number, size, shape, and location of aneurysms), and patient characteristics (geographical region, hypertension, smoking history, alcohol use, prior history of rupture).[122] In the US Registry, among patients with intracranial aneurysm, 43% were ⩾ 5 mm and 19% were located in the posterior circulation, a high-risk feature.[11] There are two modalities available for preventive aneurysm exclusion: surgical clipping and endovascular coiling with or without additional devices, such as regular stents or flow-diverting stents. The surgical and endovascular management of intracranial aneurysm in patients with FMD does not differ from that of patients without FMD.[123,124] Most intracranial aneurysms are amenable to coil embolization, especially with newer devices that are available to assist in the treatment of wide-necked aneurysms.[125] Surgical clipping is also feasible in many cases, and the choice of the best treatment modality depends on anatomical factors and the assessment of the neurointerventionalist as well as patient preference.[126] In the absence of intervention, patients with unruptured intracranial aneurysm are often advised to undergo follow-up imaging to monitor for aneurysm growth. However, the optimal frequency of follow-up is unknown.[122]

Renal and visceral artery aneurysms and dissection

The prevalence of visceral artery aneurysm and dissection among all comers with FMD is unknown as population-based studies are lacking. Furthermore, defining aneurysm in an artery affected by FMD is not straightforward given the tortuous and beaded appearance of arteries affected by multifocal FMD and challenges distinguishing a prominent beaded segment from a small aneurysm. Thus, although published rates of aneurysms in FMD exist, a consensus (size) definition for aneurysms in multifocal FMD does not.[1,2] Notwithstanding, within the US Registry, aneurysm, dissection or both were present in 41.7% of patients; in the ARCADIA Registry, aneurysms were present in 26% whereas dissections were present in 15.1% of patients.[1,2] Aneurysms may be asymptomatic or present with distal embolization of thrombotic content or rupture.

Renal and visceral artery dissection. Renal or visceral artery dissection may be asymptomatic or present with distal thromboembolic events (e.g. renal or splenic infarct). Renal infarction, often related to underlying dissection, may be an initial manifestation of renal FMD.[127,128] In the US Registry, renal artery dissection was the presenting sign of FMD in 3.1% of patients.[4] In a French single-center series including 186 patients with renal infarction, dissection was observed in 76 patients (40.8%) and occlusion in 75 (40.3%).[127] Predominant renal artery lesions (n = 151; 81.2%) were atherosclerotic disease (n = 52; 34.4%) followed by dissecting hematoma (n = 35; 23.2%) and FMD (n = 29; 19.2%). Renal artery dissection and infarction may be a more common presentation of FMD in men than women.[3] In a series of 42 patients with visceral artery dissection, aneurysm was rare and only two patients had evidence of underlying FMD.[129] Notably, not all patients were screened for FMD.

As discussed above, patients with FMD generally should receive an antiplatelet agent. If a renal or visceral artery dissection is detected, short-term (e.g. 3–6 months) anticoagulation may be prescribed empirically, particularly in the setting of distal thromboembolic lesions, followed by long-term antiplatelet therapy. Others prefer antiplatelet therapy (i.e. aspirin alone or in combination with clopidogrel) for initial treatment of renal or visceral artery dissection.[130,131] Future studies are needed given data comparing anticoagulation and antiplatelet agents after CeAD; but at this time, there are inadequate data to make a consensus point for renal and visceral artery dissection.[113] As is the case for patients without FMD, the majority of renal and visceral artery dissections in patients with FMD are managed with medical therapy and surveillance imaging. Interventional procedures for renal or visceral dissection are warranted if there is progressive end-organ malperfusion, progressive dissection over time, or secondary aneurysm. Potential procedures include covered stent, coil embolization, or surgical repair. However, it should be noted that renal artery dissections often occur in distal branches, which would preclude the use of stents. Recanalization of a dissected artery that supplies a portion of the kidney that is infarcted is unlikely to be beneficial.

Renal and visceral artery aneurysm. Patients with FMD who are found to have small renal or visceral artery aneurysms will require periodic clinical follow-up and surveillance imaging studies, though there are inadequate data to inform the optimal frequency of follow-up for a given aneurysm size. Maintaining adequate control of hypertension and complete smoking cessation is particularly important among patients with aneurysmal disease.

Among patients who do not have FMD, intervention for renal and visceral artery aneurysms is generally offered if the size exceeds 2 cm. This practice is based on limited data, including several small case series of patients with splenic and renal artery aneurysms, but no data exist specifically in FMD.[132,133] Also, it is important to note heightened concern for the risk of aneurysm rupture during pregnancy, and the size threshold for when to consider intervention for a renal, hepatic, or splenic aneurysm in a woman with FMD of childbearing age who is contemplating future pregnancy.[134–136] Although not based on good clinical studies, many experts in treating patients with FMD consider intervention on such aneurysms at a diameter threshold of less than 2 cm in women of childbearing age. Potential procedures to treat aneurysms include coiling, covered stents, or surgery (i.e. resection and/or bypass). Procedures should be avoided if an occluded aneurysm is detected, or if treatment may sacrifice vital organ parenchyma.

Renal angiography and revascularization

As discussed above, catheter-based angiography remains the gold standard for assessment of renal FMD. Measurement of a pressure gradient, usually with a flow wire, is necessary to avoid angioplasty of lesions, especially of the multifocal type, that are not hemodynamically significant (Figure 2). A pressure gradient of 10% of mean (aortic) pressure (i.e. Pd/Pa < 0.90) is proposed as a threshold for hemodynamically significant renal FMD for angioplasty, though it is acknowledged that this value is based upon the study of atherosclerotic renal artery stenosis and needs to be validated in the setting of FMD.[137] Further, measurement of a pressure gradient can be used to be sure the gradient is obliterated after angioplasty for both multifocal and focal FMD. Stent kinking and fracture have been reported in the setting of renal FMD.[138,139] Accordingly, in the absence of the demonstrated added value of stenting, angioplasty alone is the revascularization approach of choice for renal artery FMD, and stenting is reserved for the treatment of procedural complications, such as a flow-limiting dissection or arterial rupture. A proposed consensus-based protocol for catheter-based angiography and angioplasty for renal FMD is shown in Table 6. This protocol is based upon the clinical experience of experts at high-volume clinical centers and it is intended that this protocol will allow for standardization of diagnostic angiograms for renal FMD and for angioplasty procedures, and that prospective data will be collected to validate its use to potentially improve outcomes in these patients.

Surgery remains the primary approach in rare patients with complex FMD lesions of the arterial bifurcation or branches, stenoses associated with complex aneurysms, or following failure of angioplasty. Repeat angioplasty may be attempted following primary failure of angioplasty or recurrent stenosis; however, repeated procedures should be undertaken with caution to prevent jeopardizing future surgical options.[6,140]

Reported outcomes following revascularization for renal FMD have been variable. In a meta-analysis by Trinquart and colleagues, the rate of cure of hypertension (defined as blood pressure $< 140/90$ mmHg without medication) was only 36% after angioplasty across 11 clinical studies (range 14–85%), with the probability of being cured associated with younger patient age at the time of treatment and shorter duration of hypertension.[141] Savard and colleagues demonstrated that focal FMD was associated with a higher hypertension cure rate after angioplasty than multifocal FMD.[10] Finally, in the meta-analysis, 18% of patients underwent a repeat procedure.[141] Although it is reasonable to assume that improved case selection of patients with hemodynamically significant renal FMD for angioplasty and confirmation of obliteration of the trans-renal pressure gradient after angioplasty may improve interventional outcomes, this requires further study, and this has been identified as a priority for future FMD research initiatives (Table 7).

CONSENSUS POINT: A consensus-based protocol for catheter-based angiography and angioplasty for renal FMD is proposed (Table 6).

Care following renal angioplasty. Following renal angioplasty, aspirin 75–100 mg daily is prescribed indefinitely, though some operators empirically prescribe a short course of dual antiplatelet therapy (e.g. 4–6 weeks). Antihypertensive medications given prior to angioplasty can be usually stopped at discharge after successful angioplasty, and the need for medication is reassessed frequently at follow-up visits during the first post-procedure year. Surveillance with renal artery duplex ultrasound may include a study on the first office visit post-angioplasty (usually within 1 month) and every 6 months for 24 months, then yearly, to detect findings suggestive of restenosis. Imaging may be obtained more frequently in the setting of an unexplained increase in blood pressure and/or decline in renal function.

Spontaneous coronary artery dissection and coronary FMD

Spontaneous coronary artery dissection (SCAD). SCAD is an uncommon cause of acute myocardial infarction (AMI).[142–144] It has a strong female predilection ($>$ 90% female), with a minority of cases (~10%) occurring during or after pregnancy.[145–160] SCAD accounts for 10–25% of AMIs in women under the age of 50 years and 50% of AMIs occurring in the post-partum period.[150,155,156,158,161] It is a rare but recognized cause of sudden cardiac death.[162] Unlike in atherosclerotic AMI where the primary pathophysiologic event is the generation of luminal thrombus at sites of plaque rupture or erosion, coronary insufficiency in SCAD arises from external compression of the true lumen by the development of a false lumen within the outer third of the tunica media of the coronary vessel wall. The cause of SCAD is unknown. Familial cases have been described and rare cases are reported in association with hereditary connective tissue disorders, but most cases of SCAD are sporadic.[163] In the coronary circulation, SCAD has been shown to be associated with increased arterial tortuosity.[16]

SCAD can usually be diagnosed angiographically, although intracoronary imaging (e.g. with optical coherence tomography) can be helpful in equivocal cases (Figure 4).[164–166] Outcomes after percutaneous coronary intervention (PCI) are significantly worse than for atherosclerotic disease, primarily because of the risk of extension of the dissection and thus the false lumen.[145–147,149,150] In addition, after coronary artery bypass grafting (CABG), long-term subclinical graft failure rates appear high, probably due to competitive flow following healing of the native coronary following SCAD.[145] For these reasons, there is a growing consensus in favor of conservative (medical) management when possible (e.g. TIMI 3 flow in the affected vessel and no ongoing documented ischemia). Although most dissections appear to heal completely within 3–6 months, outcomes following AMI due to SCAD are impacted by a high reported incidence of recurrent SCAD, with 10.4% reported from 327 patients in one prospective series followed for a median 3.1 years.[99,143,145–147,149,150,167] Data on optimal medical therapy after SCAD remain limited, with initial evidence suggesting a potential role for beta-blockade and control of hypertension in reducing the recurrence risk.[99] The optimal regimen and duration of antiplatelet therapies in conservatively managed SCAD remains unclear. More

Table 7. FMD research priorities.

Genetics
- Further studies to extend the number of genes associated with FMD beyond the *PHACTR1* locus.
- Study of familial patterns of FMD, including intermediate phenotypes, and feasibility/utility of different modalities of screening relatives of patients with FMD.

Pathophysiology
- To gain a fundamental understanding of the principal molecular/pathologic processes underlying FMD (i.e. excess collagen/matrix production and/or fibrosis).
- To understand if there is biologic commonality/overlap between FMD, SCAD, and CeAD.
- Establishment of a tissue bank of pathology specimens to allow for study of the arterial wall properties associated with FMD.

Epidemiology and natural history
- Risk stratification: What are the factors that determine major adverse cardiovascular events (MI, stroke/TIA, and need for intervention) in patients with known FMD? Can we separate out 'benign' from 'severe' phenotypes, including those with increased risk of dissection/aneurysm?
- Determination of whether FMD is a progressive disease (within involved vascular beds, extension to other vascular beds) and the factors associated with disease progression.
- Determination of the prevalence of FMD in at-risk patient populations (e.g. young and middle-aged patients with stroke and TIA without apparent CV risk factors, women with severe migraine headaches).

Treatment
- Studies to explore the efficacy of antiplatelet therapy versus none for primary prevention of cardiovascular events among patients with FMD; enrollment stratified by cerebrovascular versus no cerebrovascular involvement.
- Studies to demonstrate the effectiveness of hemodynamic-guided angioplasty (i.e. pressure gradient measurement) for renal FMD in terms of clinical outcomes, including cure or control of hypertension.

CeAD, cervical artery dissection; CV, cardiovascular; FMD, fibromuscular dysplasia; MI, myocardial infarction; SCAD, spontaneous coronary artery dissection dissection; TIA, transient ischemic attack.

details on SCAD pathophysiology, diagnosis, and management can be found in recently published scientific statements.[168,169]

Relationship between SCAD and FMD. Pate and colleagues published the first case series describing findings of renal FMD in young patients presenting with acute coronary syndromes and unusual coronary lesions.[170] These unusual coronary lesions were subsequently identified as SCAD in a publication using OCT[171]. Since then there have been numerous single-institution studies that have reported the findings of multifocal FMD in the extracoronary beds of patients with SCAD.

The estimated prevalence of FMD among patients with SCAD varies according to the modality of screening for FMD. In a small study of 12 patients with SCAD who underwent whole-body MRA combined with duplex ultrasound of the renal and carotid arteries, the prevalence of FMD was ~16%.[172] In contrast, when using a combination of renal or iliac artery injection during coronary angiography or CTA/MRA, the prevalence of FMD findings among patients with SCAD ranges from 45% to 62.7%.[171,173] FMD of extracoronary vascular beds may be more frequent among those SCAD patients with a higher coronary tortuosity score.[16] In current series, the most predominantly affected vascular beds are the renal, carotid/vertebral, and iliac arteries.[95,146,173–175] In three studies in which the information was available, 29–70% of SCAD patients with FMD extracoronary lesions had involvement of two or more vascular beds.[95,171,173] Extracoronary FMD associated with SCAD appears to be mostly, if not only, of the multifocal type.[173] Finally, besides typical FMD multifocal lesions, other extracoronary vascular abnormalities, such as aneurysms, dissections, irregularities, undulations and/or tortuosity, have been reported in a substantial proportion of SCAD survivors.[95,173] Accordingly, it appears appropriate to recommend imaging of all vessels, from brain to pelvis, at least once in all patients who have had SCAD, usually with CTA or MRA, in order to assess for FMD and other non-coronary arterial abnormalities.

Whereas FMD is highly prevalent among patients with SCAD, coronary dissection is an uncommon occurrence among patients with FMD. According to the US Registry, 10.5% (25/237 dissections) of patients with arterial dissection experienced coronary dissection; however, among all patients in the Registry, coronary dissection was only reported in 2.7%.[1] Thus, it is clear that SCAD, although occurring among patients with FMD more frequently than in the general population, is still an uncommon event in large FMD patient registries. Although it is possible that coronary tortuosity is more frequent in patients with classical extracoronary FMD, the performance of non-invasive imaging modalities, such as coronary CTA, for detection of such abnormalities has not been studied and, anyhow, identification of such lesions will not influence patient management.[16,176] Therefore, at this time, screening for coronary FMD in patients without angina is not recommended.

Is there coronary FMD beyond SCAD? Though a link between FMD and SCAD has been established, more controversial is, firstly, whether SCAD is a distinct entity or simply a clinical complication of FMD, and, secondly, whether there are definite coronary manifestations of FMD other than coronary artery dissection.

A key aspect of the first controversy, whether SCAD effectively equals FMD, is the difference between the

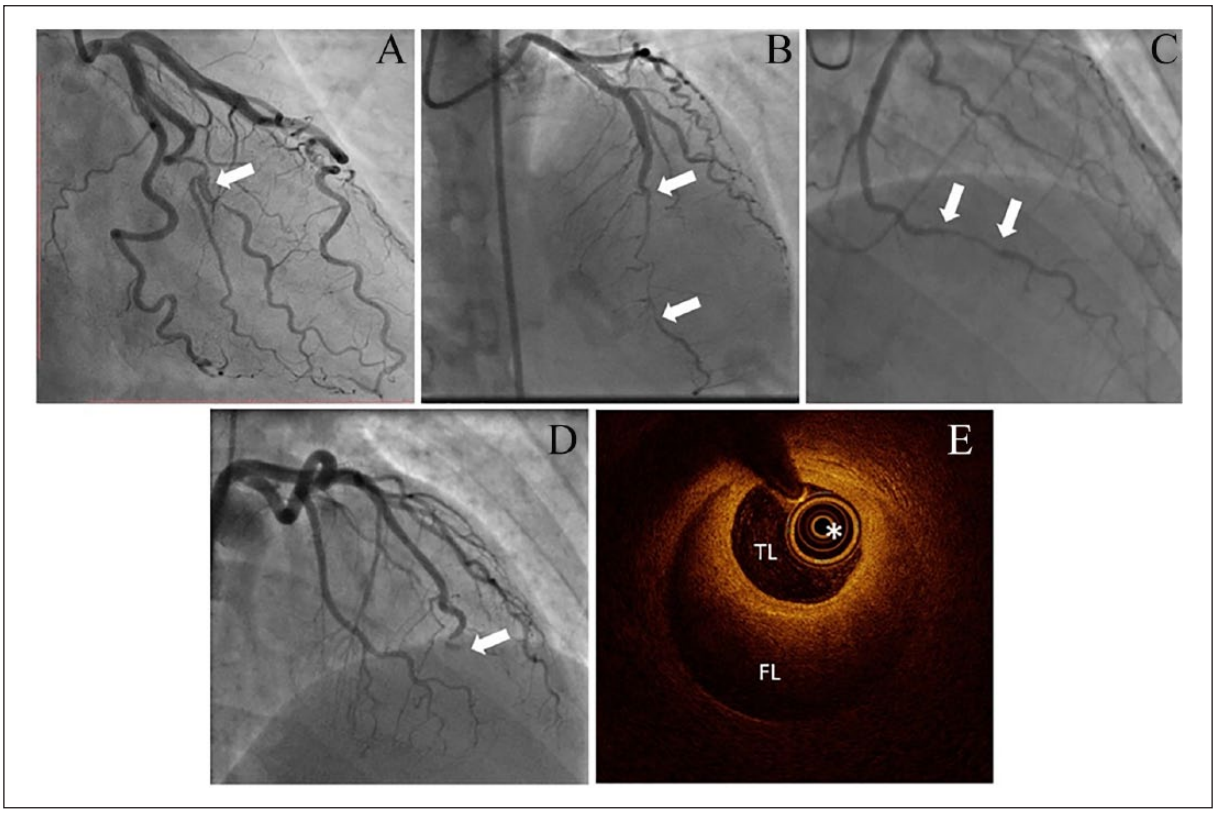

Figure 4. Angiographic classification of SCAD (arrows), proposed by Saw and colleagues.[165] Type 1 SCAD – with a dual lumen and flap in the mid-LAD coronary artery (A), type 2 SCAD with a long segment of narrowing in the mid-distal LAD with recrudescence of the vessel distally (B), and type 3 SCAD resembling an atherosclerotic lesion with diagnosis requiring intracoronary imaging (C). A fourth angiographic appearance of SCAD leading to coronary artery occlusion has been proposed.[169] In this case (D), there was a total occlusion of the LAD, with SCAD only confirmed after restoration of distal flow. (E) A typical optical coherence tomography image of SCAD, showing the imaging catheter (*) within the TL surrounded by the compressing crescentic FL.
FL, false lumen; LAD, left anterior descending; SCAD, spontaneous coronary artery dissection; TL, true lumen.

histopathological descriptions that form the historical basis of both of these conditions and the clinical and angiographic syndromes, which currently define these diagnoses. Two sites of coronary FMD that are well described histologically are aorto-ostial coronary left mainstem FMD and small vessel FMD affecting arterial branches supplying the conduction system (e.g. atrioventricular and sinoatrial nodal arteries).[177–187] Both have been associated with sudden cardiac death in rare post mortem reports in adults and children. However, although histopathologically consistent with FMD, these patterns of disease appear distinct from the clinical phenotype of both 'typical' SCAD and 'classical' renal and/or cerebrovascular multifocal FMD. Thus, these histopathological entities probably represent distinct clinical entities.

Among patients with SCAD who are found to have FMD, it is unclear if SCAD occurs at sites of pre-existent subclinical coronary FMD or, more generally, if coronary manifestations can be definitively attributed to FMD per se. A number of case reports describe coronary histology consistent with FMD in post mortem cases of SCAD, but others do not.[162,188–192] Angiographic and intracoronary imaging abnormalities have been described from patients with SCAD and FMD, but such findings do not appear universal among patients with SCAD and have not been correlated with histologic findings.[193–195] Furthermore, series reporting follow-up imaging after conservatively managed SCAD usually describe complete restoration of angiographic coronary architecture with healing of the false lumen, although this could miss histological abnormalities which do not affect luminal geometry.[145,146,149,150,153] Therefore, pending detailed post mortem SCAD series, coupled with a systematic study of the coronary vascular bed in patients with FMD without SCAD, coronary FMD remains an elusive entity.

CONSENSUS POINT: Patients who have had SCAD should undergo imaging of all vessels from brain to pelvis, at least once and usually with CTA or contrast-enhanced MRA, to assess for FMD and other non-coronary arterial abnormalities.

Follow-up and longitudinal care

FMD is a chronic vascular disease that requires longitudinal care focused on medical therapy as well as periodic imaging of affected vascular beds. It is the consensus of the writing committee that after initial comprehensive evaluation, patients with FMD be seen in follow-up at least annually by a health care provider who has experience in management of this disease. Patients with more severe symptoms or disease may require more frequent follow-up. Clinical evaluation during follow-up should include: history of interval vascular events, evaluation of symptoms

that may be associated with FMD (e.g. migraine headaches, neck pain, pulsatile tinnitus, claudication, mesenteric angina), and assessment of blood pressure control. Evaluation should also include measurement of blood pressure and vascular physical examination (for pulse deficits and bruits). Adherence to medical therapy, particularly to an antiplatelet agent and medications for treatment of hypertension, should be assessed, along with potential adverse reactions to these medications. For patients with renal artery involvement, blood chemistries for renal function and serum electrolytes should be monitored at least annually, along with periodic urinalysis to screen for albuminuria in patients with other concomitant risk factors. Education should include the review of potential warning signs and symptoms of TIA, stroke, and arterial dissection (CeAD or SCAD), and the need to seek immediate medical care should any develop.

At this time, data are insufficient to recommend a specific algorithm for follow-up imaging studies for patients with FMD. Imaging surveillance, including choice of imaging modality and frequency of imaging, must be customized to each patient based upon the nature and severity of symptoms, distribution of vascular bed involvement, extent and severity of arterial lesions, and the presence or absence of arterial dissections or aneurysms (and aneurysm size), as well as local imaging resources and experience. Patients who have undergone revascularization procedures, such as renal angioplasty, may require more frequent imaging surveillance, particularly within the 2 years following the procedure (see above).

Follow-up during pregnancy. Pre-conceptive counseling with a health care provider with experience in the management of FMD as well as a high-risk obstetrician or maternal fetal medicine specialist may be helpful for patients with FMD who are contemplating pregnancy, particularly patients with high-risk features such as prior history of CeAD or SCAD or those with poorly controlled hypertension. Patients with FMD who decide to become pregnant require more intensive follow-up throughout pregnancy with a customized care plan and close monitoring by a team of health care providers that generally includes a high-risk obstetrician or maternal fetal medicine specialist and a provider with expertise in FMD. A plan for delivery, including planned caesarian section or facilitated second phase of labor for vaginal delivery, should be customized to the specifics of each patient's case, including prior history of dissection or presence of an aneurysm. Though there are limited data available, literature suggests a significantly increased risk of pre-eclampsia among women with renal FMD.[196,197] Monitoring for the development of hypertension throughout pregnancy and management of pregnancy-related hypertension requires frequent clinical follow-up throughout each trimester of pregnancy and in the immediate post-partum period.

CONSENSUS POINT: Patients with FMD should be seen in follow-up at least annually. Follow-up includes clinical assessment, assessment of renal function (for renal artery FMD), and imaging. At this time, there is insufficient data to recommend specific algorithms for modality and frequency of imaging studies in the follow-up of FMD. The timing of follow-up imaging should be customized to each patient's pattern and severity of disease, including the need for monitoring of aneurysms or dissections or following revascularization, as well as local imaging resources and experience.

Impact of FMD on quality of life and the role of patient associations

See the online supplement for discussion of quality of life considerations and international FMD patient associations.

Emerging biomarkers and future directions

See the online supplement for discussion of ultrasound echo tracking and the 'triple signal', fibroblast-based investigation, and ultra-high resolution ultrasound of the artery wall.

Current research priorities

Survey of the writing committee initially identified 28 research topics for further investigation ranging from studies related to the pathogenesis (genetic and environmental) of FMD, its epidemiology and natural history, diagnosis and clinical management, and strategies to optimize patient and health care provider awareness. These topics were reviewed and ranked by the full writing committee to identify its top 10 research priorities for FMD (Table 7). It is intended that this list serves to motivate basic, clinical, and translational investigators to pursue the study of FMD, and that scientific organizations may consider these topics for future strategic research and funding initiatives.

Acknowledgements

The authors acknowledge Dr Christopher Bajzer (Cleveland Clinic), Dr Robert Lookstein (Mount Sinai Medical Center), Dr Alan Matsumoto (University of Virginia), and Dr Sanjay Misra (Mayo Clinic) for their insights on renal FMD and prior participation in working groups of the International FMD Research Network focused on renal angiography and angioplasty, which formed a foundation for Table 6. The authors thank Ms Marianne Khoury (Cleveland Clinic) for her assistance in coordinating and formatting the manuscript; Dr Laurent Toubiana (INSERM UMRS 1142 LIMICS/IRSAN, Paris, France) and Dr Silvia Di Monaco (Cliniques Universitaires Saint-Luc, Brussels, Belgium/AOU Città della Salute e della Scienza, Turin, Italy) for data extraction and analysis of the European FMD Registry (Tables 4 and 5); and Dr Xiaokui Gu (University of Michigan) for data extraction and analysis of the US Registry for FMD (Tables 4 and 5). They also wish to acknowledge Dr Pasquale Scoppettuolo (Hôpital Erasme, Brussels, Belgium) for providing panel C of Figure 1, Dr Robert Lookstein for providing panels A–C of Figure 2, Professor Patrick Chenu and Professor Frank Hammer (Cliniques Universitaires Saint-Luc, Brussels, Belgium) for panels A and C of Figure 3, respectively, and Dr Lucas

Aparicio (Hospital Italiano, Buenos Aires, Argentina) for panel B of the same figure. Dr David Adlam wishes to acknowledge the ESC-ACCA SCAD study group and the BeatSCAD organization. Finally, Mrs Cathlin Jamison wishes to acknowledge Dr Véronique Godin (FMD-Be) for fruitful discussion and contribution to the section on the role of patient associations. The authors thank all of the patients who have participated in international registries and research studies of FMD, CeAD, and SCAD, as these studies have greatly helped to advance our understanding of these diseases.

Declaration of conflicting interests

The authors declared the following potential conflicts of interest with respect to the research, authorship, and/or publication of this article: Drs Gornik and Olin are non-compensated members of the Medical Advisory Board of the FMD Society of America (FMDSA), a non-profit organization. Ms Pamela Mace is an employee of the FMDSA. The other authors declared no conflict of interest.

Funding

The authors have disclosed the following sources of funding for the research, authorship, and/or publication of this article. Dr. Froehlich has received funding to the Michigan Clinical Outcomes Research and Reporting Program (MCORRP) from the FMDSA to support the US Registry for FMD. Dr. Ganesh has received support from HL139672 and the Doris Duke Charitable Foundation. The other authors have no financial disclosures related to this article.

Supplemental material

The supplementary material is available online with the article.

References

1. Kadian-Dodov D, Gornik HL, Gu X, et al. Dissection and aneurysm in patients with fibromuscular dysplasia: Findings from the U.S. Registry for FMD. *J Am Coll Cardiol* 2016; 68: 176–185.
2. Plouin PF, Baguet JP, Thony F, et al. High prevalence of multiple arterial bed lesions in patients with fibromuscular dysplasia: The ARCADIA Registry (Assessment of Renal and Cervical Artery Dysplasia). *Hypertension* 2017; 70: 652–658.
3. Kim ESH, Olin JW, Froehlich JB, et al. Clinical manifestations of fibromuscular dysplasia vary by patient sex: A report of the United States Registry for fibromuscular dysplasia. *J Am Coll Cardiol* 2013; 62: 2026–2028.
4. Olin JW, Froehlich J, Gu X, et al. The United States Registry for Fibromuscular Dysplasia: Results in the first 447 patients. *Circulation* 2012; 125: 3182–3190.
5. Olin JW, Gornik HL, Bacharach JM, et al. Fibromuscular dysplasia: State of the science and critical unanswered questions: A scientific statement from the American Heart Association. *Circulation* 2014; 129: 1048–1078.
6. Persu A, Giavarini A, Touze E, et al. European consensus on the diagnosis and management of fibromuscular dysplasia. *J Hypertens* 2014; 32: 1367–1378.
7. Harrison EG Jr, McCormack LJ. Pathologic classification of renal arterial disease in renovascular hypertension. *Mayo Clin Proc* 1971; 46: 161–167.
8. McCormack LJ, Poutasse EF, Meaney TF, et al. A pathologic–arteriographic correlation of renal arterial disease. *Am Heart J* 1966; 72: 188–198.
9. Stanley JC, Gewertz BL, Bove EL, et al. Arterial fibrodysplasia. Histopathologic character and current etiologic concepts. *Arch Surg* 1975; 110: 561–566.
10. Savard S, Steichen O, Azarine A, et al. Association between 2 angiographic subtypes of renal artery fibromuscular dysplasia and clinical characteristics. *Circulation* 2012; 126: 3062–3069.
11. Lather HD, Gornik HL, Olin JW, et al. Prevalence of intracranial aneurysm in women with fibromuscular dysplasia: A report from the US Registry for Fibromuscular Dysplasia. *JAMA Neurol* 2017; 74: 1081–1087.
12. Sethi SS, Lau JF, Godbold J, et al. The S curve: A novel morphological finding in the internal carotid artery in patients with fibromuscular dysplasia. *Vasc Med* 2014; 19: 356–362.
13. Metz H, Murray-Leslie RM, Bannister RG, et al. Kinking of the internal carotid artery. *Lancet* 1961; i: 424–426.
14. George B, Mourier KL, Gelbert F, et al. Vascular abnormalities in the neck associated with intracranial aneurysms. *Neurosurgery* 1989; 24: 499–508.
15. Morris SA, Orbach DB, Geva T, et al. Increased Vertebral Artery Tortuosity Index is associated with adverse outcomes in children and young adults with connective tissue disorders. *Circulation* 2011; 124: 388–396.
16. Eleid MF, Guddeti RR, Tweet MS, et al. Coronary artery tortuosity in spontaneous coronary artery dissection: Angiographic characteristics and clinical implications. *Circ Cardiovasc Interv* 2014; 7: 656–662.
17. Groves SS, Jain AC, Warden BE, et al. Severe coronary tortuosity and the relationship to significant coronary artery disease. *W V Med J* 2009; 105: 14–17.
18. Li Y, Shen C, Ji Y, et al. Clinical implication of coronary tortuosity in patients with coronary artery disease. *PLoS One* 2011; 6: e24232.
19. Morris SA. Arterial tortuosity in genetic arteriopathies. *Curr Opin Cardiol* 2015; 30: 587–593.
20. Meester JAN, Verstraeten A, Schepers D, et al. Differences in manifestations of Marfan syndrome, Ehlers-Danlos syndrome, and Loeys-Dietz syndrome. *Ann Cardiothorac Surg* 2017; 6: 582–594.
21. Perdu J, Boutouyrie P, Bourgain C, et al. Inheritance of arterial lesions in renal fibromuscular dysplasia. *J Hum Hypertens* 2007; 21: 393–400.
22. Mettinger KL, Ericson K. Fibromuscular dysplasia and the brain. I. Observations on angiographic, clinical and genetic characteristics. *Stroke* 1982; 13: 46–52.
23. Gladstien K, Rushton AR, Kidd KK. Penetrance estimates and recurrence risks for fibromuscular dysplasia. *Clin Genet* 1980; 17: 115–116.
24. Rushton AR. The genetics of fibromuscular dysplasia. *Arch Intern Med* 1980; 140: 233–236.
25. Major P, Genest J, Cartier P, et al. Hereditary fibromuscular dysplasia with renovascular hypertension. *Ann Intern Med* 1977; 86: 583.
26. Poloskey SL, Kim E, Sanghani R, et al. Low yield of genetic testing for known vascular connective tissue disorders in patients with fibromuscular dysplasia. *Vasc Med* 2012; 17: 371–378.
27. Ganesh SK, Morissette R, Xu Z, et al. Clinical and biochemical profiles suggest fibromuscular dysplasia is a systemic disease with altered TGF-β expression and connective tissue features. *FASEB J* 2014; 28: 3313–3324.
28. McKenzie GA, Oderich GS, Kawashima A, et al. Renal artery fibromuscular dysplasia in 2,640 renal donor subjects: A CT angiography analysis. *J Vasc Interv Radiol* 2013; 24: 1477–1480.

29. Hendricks NJ, Matsumoto AH, Angle JF, et al. Is fibromuscular dysplasia underdiagnosed? A comparison of the prevalence of FMD seen in CORAL trial participants versus a single institution population of renal donor candidates. *Vasc Med* 2014; 19: 363–367.
30. Kiando SR, Tucker NR, Castro-Vega L-J, et al. *PHACTR1* is a genetic susceptibility locus for fibromuscular dysplasia supporting its complex genetic pattern of inheritance. *PLOS Genet* 2016; 12: e1006367.
31. Gupta RM, Hadaya J, Trehan A, et al. A genetic variant associated with five vascular diseases is a distal regulator of endothelin-1 gene expression. *Cell* 2017; 170: 522–533.e15.
32. Kathiresan S, Voight BF, Purcell S, et al. Genome-wide association of early-onset myocardial infarction with single nucleotide polymorphisms and copy number variants. *Nat Genet* 2009; 41: 334–341.
33. Deloukas P, Kanoni S, Willenborg C, et al. Large-scale association analysis identifies new risk loci for coronary artery disease. *Nat Genet* 2013; 45: 25–33.
34. Nikpay M, Goel A, Won HH, et al. A comprehensive 1,000 Genomes-based genome-wide association meta-analysis of coronary artery disease. *Nat Genet* 2015; 47: 1121–1130.
35. Surendran P, Drenos F, Young R, et al. Trans-ancestry meta-analyses identify rare and common variants associated with blood pressure and hypertension. *Nat Genet* 2016; 48: 1151–1161.
36. Debette S, Kamatani Y, Metso TM, et al. Common variation in *PHACTR1* is associated with susceptibility to cervical artery dissection. *Nat Genet* 2015; 47: 78–83.
37. Anttila V, Winsvold BS, Gormley P, et al. Genome-wide meta-analysis identifies new susceptibility loci for migraine. *Nat Genet* 2013; 45: 912–917.
38. Mackay A, Brown J, Cumming A, et al. Smoking and renal artery stenosis. *Br Med J* 1979; 2: 770.
39. Sang CN, Whelton PK, Hamper UM, et al. Etiologic factors in renovascular fibromuscular dysplasia. A case–control study. *Hypertension* 1989; 14: 472–479.
40. Savard S, Azarine A, Jeunemaitre X, et al. Association of smoking with phenotype at diagnosis and vascular interventions in patients with renal artery fibromuscular dysplasia. *Hypertension* 2013; 61: 1227–1232.
41. O'Connor S, Gornik HL, Froehlich JB, et al. Smoking and adverse outcomes in fibromuscular dysplasia: U.S. Registry report. *J Am Coll Cardiol* 2016; 67: 1750–1751.
42. Luscher TF, Lie JT, Stanson AW, et al. Arterial fibromuscular dysplasia. *Mayo Clin Proc* 1987; 62: 931–952.
43. Silhol F, Sarlon-Bartoli G, Daniel L, et al. Intranuclear expression of progesterone receptors in smooth muscle cells of renovascular fibromuscular dysplasia: A pilot study. *Ann Vasc Surg* 2015; 29: 830–835.
44. Kaufman JJ, Maxwell MH. Upright aortography in the study of nephroptosis, stenotic lesions of the renal artery, and hypertension. *Surgery* 1963; 53: 736–742.
45. Shimabukuro M. A new plausible link between lysophosphatidylcholine, TGF-β, and fibromuscular dysplasia. *J Atheroscler Thromb* 2016; 23: 665–667.
46. Slavin RE, Saeki K, Bhagavan B, et al. Segmental arterial mediolysis: A precursor to fibromuscular dysplasia? *Mod Pathol* 1995; 8: 287–294.
47. Hata A, Noda M, Moriwaki R, et al. Angiographic findings of Takayasu arteritis: New classification. *Int J Cardiol* 1996; 54(Suppl): S155–163.
48. Salvarani C, Pipitone N, Versari A, et al. Clinical features of polymyalgia rheumatica and giant cell arteritis. *Nat Rev Rheumatol* 2012; 8: 509–521.
49. Collins RT 2nd. Cardiovascular disease in Williams syndrome. *Circulation* 2013; 127: 2125–2134.
50. Gutmann DH, Ferner RE, Listernick RH, et al. Neurofibromatosis type 1. *Nat Rev Dis Primers* 2017; 3: 17004.
51. Kamath BM, Spinner NB, Emerick KM, et al. Vascular anomalies in Alagille syndrome: A significant cause of morbidity and mortality. *Circulation* 2004; 109: 1354–1358.
52. MacCarrick G, Black JH 3rd, Bowdin S, et al. Loeys-Dietz syndrome: A primer for diagnosis and management. *Genet Med* 2014; 16: 576–587.
53. Loeys BL, Schwarze U, Holm T, et al. Aneurysm syndromes caused by mutations in the TGF-β receptor. *N Engl J Med* 2006; 355: 788–798.
54. Beighton P, De Paepe A, Steinmann B, et al. Ehlers-Danlos syndromes: Revised nosology, Villefranche, 1997. Ehlers-Danlos National Foundation (USA) and Ehlers-Danlos Support Group (UK). *Am J Med Genet* 1998; 77: 31–37.
55. Shalhub S, Black JH 3rd, Cecchi AC, et al. Molecular diagnosis in vascular Ehlers-Danlos syndrome predicts pattern of arterial involvement and outcomes. *J Vasc Surg* 2014; 60: 160–169.
56. Pepin M, Schwarze U, Superti-Furga A, et al. Clinical and genetic features of Ehlers-Danlos syndrome type IV, the vascular type. *N Engl J Med* 2000; 342: 673–680.
57. Sharma AM, Gornik HL. Standing arterial waves is NOT fibromuscular dysplasia. *Circ Cardiovasc Interv* 2012; 5: e9–e11.
58. Shenoy S, Sharma A, Norton P, et al. Standing waves are not distinctive to conventional angiograms. *Vasc Med* 2018; 23: 183–184.
59. Weinberg I, Gu X, Giri J, et al. Anti-platelet and anti-hypertension medication use in patients with fibromuscular dysplasia: Results from the United States Registry for Fibromuscular Dysplasia. *Vasc Med* 2015; 20: 447–453.
60. Green R, Gu X, Kline-Rogers E, et al. Differences between the pediatric and adult presentation of fibromuscular dysplasia: Results from the US Registry. *Pediatr Nephrol* 2016; 31: 641–650.
61. Persu A, Van der Niepen P, Touze E, et al. Revisiting fibromuscular dysplasia: Rationale of the European Fibromuscular Dysplasia Initiative. *Hypertension* 2016; 68: 832–839.
62. Toubiana L, Ugon A, Giavarini A, et al. A 'pivot' model to set up large scale rare diseases information systems: Application to the Fibromuscular Dysplasia Registry. *Stud Health Technol Inform* 2015; 210: 887–891.
63. Jaulent MC, Assele-Kama A, Savard S, et al. Building a semantic interoperability framework for care and research in fibromuscular dysplasia. *Stud Health Technol Inform* 2015; 216: 217–221.
64. Warchol-Celinska E, Hanus K, Florczak E, et al. The Polish Registry for Fibromuscular Dysplasia (ARCADIA-POL study) – Distribution of vascular bed involvement and complications in patients with fibromuscular dysplasia. *J Hypertens* 2017; 35: e151–e152 [PP.09.05].
65. Shivapour DM, Erwin P, Kim E. Epidemiology of fibromuscular dysplasia: A review of the literature. *Vasc Med* 2016; 21: 376–381.
66. Beregi J, Louvegny S, Gautier C, et al. Fibromuscular dysplasia of the renal arteries: Comparison of helical CT angiography and arteriography. *AJR Am J Roentgenol* 1999; 172: 27–34.

67. Sabharwal R, Vladica P, Coleman P. Multidetector spiral CT renal angiography in the diagnosis of renal artery fibromuscular dysplasia. *Eur J Radiol* 2007; 61: 520–527.
68. Willoteaux S, Faivre-Pierret M, Moranne O, et al. Fibromuscular dysplasia of the main renal arteries: Comparison of contrast-enhanced MR angiography with digital subtraction angiography. *Radiology* 2006; 241: 922–929.
69. Bolen MA, Brinza E, Renapurkar RD, et al. Screening CT angiography of the aorta, visceral branch vessels, and pelvic arteries in fibromuscular dysplasia. *JACC Cardiovasc Imaging* 2017; 10: 554–561.
70. Slovut DP, Olin JW. Fibromuscular dysplasia. *N Engl J Med* 2004; 350: 1862–1871.
71. Bejot Y, Aboa-Eboule C, Debette S, et al. Characteristics and outcomes of patients with multiple cervical artery dissection. *Stroke* 2014; 45: 37–41.
72. Southerland AM, Meschia JF, Worrall BB. Shared associations of nonatherosclerotic, large-vessel, cerebrovascular arteriopathies: Considering intracranial aneurysms, cervical artery dissection, moyamoya disease and fibromuscular dysplasia. *Curr Opin Neurol* 2013; 26: 13–28.
73. Debette S. Pathophysiology and risk factors of cervical artery dissection: What have we learnt from large hospital-based cohorts? *Curr Opin Neurol* 2014; 27: 20–28.
74. Practice parameter: the utility of neuroimaging in the evaluation of headache in patients with normal neurologic examinations (summary statement). Report of the Quality Standards Subcommittee of the American Academy of Neurology. *Neurology* 1994; 44: 1353–1354.
75. Ehrenfeld WK, Wylie EJ. Fibromuscular dysplasia of the internal carotid artery: Surgical management. *Arch Surg* 1974; 109: 676–681.
76. Joux J, Chausson N, Jeannin S, et al. Carotid-bulb atypical fibromuscular dysplasia in young Afro-Caribbean patients with stroke. *Stroke* 2014; 45: 3711–3713.
77. Haussen DC, Grossberg JA, Bouslama M, et al. Carotid web (intimal fibromuscular dysplasia) has high stroke recurrence risk and is amenable to stenting. *Stroke* 2017; 48: 3134–3137.
78. Lenck S, Labeyrie MA, Saint-Maurice JP, et al. Diaphragms of the carotid and vertebral arteries: An under-diagnosed cause of ischaemic stroke. *Eur J Neurol* 2014; 21: 586–593.
79. Singh D, Trivedi A, Qazi E, et al. Carotid webs and recurrent ischemic strokes in the era of CT angiography. *Am J Neuroradiol* 2015; 36: 2134–2139.
80. Joux J, Boulanger M, Jeannin S, et al. Association between carotid bulb diaphragm and ischemic stroke in young Afro-Caribbean patients: A population-based case-control study. *Stroke* 2016; 47: 2641–2644.
81. Wirth FP, Miller WA, Russell AP. Atypical fibromuscular hyperplasia. Report of two cases. *J Neurosurg* 1981; 54: 685–689.
82. Kliewer MA, Carroll BA. Ultrasound case of the day. Internal carotid artery web (atypical fibromuscular dysplasia). *Radiographics* 1991; 11: 504–505.
83. Ehrenfeld WK, Stoney RJ, Wylie EJ. Fibromuscular hyperplasia of the internal carotid artery. *Arch Surg* 1967; 95: 284–287.
84. Touze E, Oppenheim C, Trystram D, et al. Fibromuscular dysplasia of cervical and intracranial arteries. *Int J Stroke* 2010; 5: 296–305.
85. Chaari D, Baud JM, Deschamps L, et al. Carotid diaphragm: Atypical fibromuscular dysplasia or atheromatous lesions? *Rev Neurol (Paris)* 2017; 173: 230–233.
86. Moore EK, Gu X, Olin JW, et al. Registry findings of fibromuscular dysplasia of the mesenteric arteries. *Vasc Med* 2014; 19: 224–225.
87. Crowhurst TD, Ho P. Hepatic artery dissection in a 65-year-old woman with acute pancreatitis. *Ann Vasc Surg* 2011; 25: 386.e17–21.
88. Pinkerton JA Jr, Wood WG, Fowler D. Fibrodysplasia with dissecting aneurysm of the hepatic artery. *Surgery* 1976; 79: 721–723.
89. Brinza E, Grabinski V, Durga S, et al. Lower extremity fibromuscular dysplasia: Clinical manifestations, diagnostic testing, and approach to management. *Angiology* 2017; 68: 722–727.
90. Okazaki J, Guntani A, Homma K, et al. Fibromuscular dysplasia of the lower extremities. *Ann Vasc Dis* 2011; 4: 143–149.
91. Nguyen N, Sharma A, West JK, et al. Presentation, clinical features, and results of intervention in upper extremity fibromuscular dysplasia. *J Vasc Surg* 2017; 66: 554–563.
92. Kolluri R, Ansel G. Fibromuscular dysplasia of bilateral brachial arteries—A case report and literature review. *Angiology* 2004; 55: 685–689.
93. Shin JS, Han EM, Min BZ, et al. Fibromuscular dysplasia of bilateral brachial arteries treated with surgery and consecutive thrombolytic therapy. *Ann Vasc Surg* 2007; 21: 93–96.
94. Reilly JM, McGraw DJ, Sicard GA. Bilateral brachial artery fibromuscular dysplasia. *Ann Vasc Surg* 1993; 7: 483–487.
95. Liang JJ, Prasad M, Tweet MS, et al. A novel application of CT angiography to detect extracoronary vascular abnormalities in patients with spontaneous coronary artery dissection. *J Cardiovasc Comput Tomogr* 2014; 8: 189–197.
96. Williams B, Mancia G, Spiering W, et al. 2018 ESC/ESH Guidelines for the management of arterial hypertension. *J Hypertens* 2018; 36: 1953–2041.
97. Whelton PK, Carey RM, Aronow WS, et al. 2017 ACC/AHA/AAPA/ABC/ACPM/AGS/APhA/ASH/ASPC/NMA/PCNA guideline for the prevention, detection, evaluation, and management of high blood pressure in adults: a report of the American College of Cardiology/American Heart Association Task Force on Clinical Practice Guidelines. *J Am Coll Cardiol* 2018; 71: e127–e248.
98. Dworkin LD, Cooper CJ. Clinical practice. Renal-artery stenosis. *N Engl J Med* 2009; 361: 1972–1978.
99. Saw J, Humphries K, Aymong E, et al. Spontaneous coronary artery dissection: Clinical outcomes and risk of recurrence. *J Am Coll Cardiol* 2017; 70: 1148–1158.
100. Swan K, Gu X, Kline-Rogers E, et al. Abstract 099: Prevalence of headaches in patients with fibromuscular dysplasia: A Report from the US Registry for FMD. *Circ Cardiovasc Qual Outcomes* 2017; 10: A099-A.
101. O'Connor SC, Poria N, Gornik HL. Fibromuscular dysplasia: An update for the headache clinician. *Headache* 2015; 55: 748–755.
102. Mahmood RZ, Olin J, Gu X, et al. Unraveling pulsatile tinnitus in FMD: A report of the United States Registry for Fibromuscular Dysplasia. *J Am Coll Cardiol* 2014; 63: A2060.
103. Makar SK, Mukundan G, Gore G. Treatment of tinnitus: A scoping review. *Int Tinnitus J* 2017; 21: 144–156.
104. Searchfield GD, Durai M, Linford T. A state-of-the-art review: Personalization of tinnitus sound therapy. *Front Psychol* 2017; 8: 1599.
105. Sismanis A. Pulsatile tinnitus: Contemporary assessment and management. *Curr Opin Otolaryngol Head Neck Surg* 2011; 19: 348–357.

106. Stein LH, Berger J, Tranquilli M, et al. Effect of statin drugs on thoracic aortic aneurysms. *Am J Cardiol* 2013; 112: 1240–1245.
107. Stone NJ, Robinson J, Lichtenstein AH, et al. 2013 ACC/AHA Guideline on the Treatment of Blood Cholesterol to Reduce Atherosclerotic Cardiovascular Risk in Adults. A Report of the American College of Cardiology/American Heart Association Task Force on Practice Guidelines 2013. *J Am Coll Cardiol* 2014; 63(25 Pt B): 2889–2934.
108. Catapano AL, Graham I, De Backer G, et al. 2016 ESC/EAS guidelines for the management of dyslipidaemias. *Eur Heart J* 2016; 37: 2999–3058.
109. Lightwood JM, Glantz SA. Short-term economic and health benefits of smoking cessation: Myocardial infarction and stroke. *Circulation* 1997; 96: 1089–1096.
110. Rothwell DM, Bondy SJ, Williams JI. Chiropractic manipulation and stroke: A population-based case-control study. *Stroke* 2001; 32: 1054–1060.
111. Blacker DJ, Wijdicks EF. A ripping roller coaster ride. *Neurology* 2003; 61: 1255.
112. Debette S, Leys D. Cervical-artery dissections: Predisposing factors, diagnosis, and outcome. *Lancet Neurol* 2009; 8: 668–678.
113. Markus HS, Hayter E, Levi C, et al. Antiplatelet treatment compared with anticoagulation treatment for cervical artery dissection (CADISS): A randomised trial. *Lancet Neurol* 2015; 14: 361–367.
114. Lin J, Sun Y, Zhao S, et al. Safety and efficacy of thrombolysis in cervical artery dissection-related ischemic stroke: A meta-analysis of observational studies. *Cerebrovasc Dis* 2016; 42: 272–279.
115. Robertson JJ, Koyfman A. Cervical artery dissections: A review. *J Emerg Med* 2016; 51: 508–518.
116. Powers WJ, Rabinstein AA, Ackerson T, et al. 2018 Guidelines for the early management of patients with acute ischemic stroke: A guideline for healthcare professionals from the American Heart Association/American Stroke Association. *Stroke* 2018; 49: e46–e110.
117. Caprio FZ, Bernstein RA, Alberts MJ, et al. Efficacy and safety of novel oral anticoagulants in patients with cervical artery dissections. *Cerebrovasc Dis* 2014; 38: 247–253.
118. Rahme RJ, Aoun SG, McClendon J Jr, et al. Spontaneous cervical and cerebral arterial dissections: Diagnosis and management. *Neuroimaging Clin N Am* 2013; 23: 661–671.
119. Schirmer CM, Atalay B, Malek AM. Endovascular recanalization of symptomatic flow-limiting cervical carotid dissection in an isolated hemisphere. *Neurosurg Focus* 2011; 30: E16.
120. Touze E, Randoux B, Meary E, et al. Aneurysmal forms of cervical artery dissection: Associated factors and outcome. *Stroke* 2001; 32: 418–423.
121. Larsson SC, King A, Madigan J, et al. Prognosis of carotid dissecting aneurysms: Results from CADISS and a systematic review. *Neurology* 2017; 88: 646–652.
122. Etminan N, Rinkel GJ. Unruptured intracranial aneurysms: Development, rupture and preventive management. *Nat Rev Neurol* 2016; 12: 699–713.
123. Etminan N, Brown RD Jr, Beseoglu K, et al. The unruptured intracranial aneurysm treatment score: A multidisciplinary consensus. *Neurology* 2015; 85: 881–889.
124. Connolly ES Jr, Rabinstein AA, Carhuapoma JR, et al. Guidelines for the management of aneurysmal subarachnoid hemorrhage: A guideline for healthcare professionals from the American Heart Association/American Stroke Association. *Stroke* 2012; 43: 1711–1737.
125. Lv X, Yang H, Liu P, et al. Flow-diverter devices in the treatment of intracranial aneurysms: A meta-analysis and systematic review. *Neuroradiol J* 2016; 29: 66–71.
126. Shivashankar R, Miller TR, Jindal G, et al. Treatment of cerebral aneurysms—Surgical clipping or endovascular coiling: The guiding principles. *Semin Neurol* 2013; 33: 476–487.
127. Faucon AL, Bobrie G, Jannot AS, et al. Cause of renal infarction: A retrospective analysis of 186 consecutive cases. *J Hypertens* 2018; 36: 634–640.
128. Lengelé J-P, Christophe J-L, Persu A. Renal infarction management: Towards an etiological approach? *J Hypertens* 2018; 36: 490–492.
129. DeCarlo C, Ganguli S, Borges JC, et al. Presentation, treatment, and outcomes in patients with spontaneous isolated celiac and superior mesenteric artery dissection. *Vasc Med* 2017; 22: 505–511.
130. Cavalcante RN, Motta-Leal-Filho JM, De Fina B, et al. Systematic literature review on evaluation and management of isolated spontaneous celiac trunk dissection. *Ann Vasc Surg* 2016; 34: 274–279.
131. Oh YK, Yang CW, Kim YL, et al. Clinical characteristics and outcomes of renal infarction. *Am J Kidney Dis* 2016; 67: 243–250.
132. Lakin RO, Bena JF, Sarac TP, et al. The contemporary management of splenic artery aneurysms. *J Vasc Surg* 2011; 53: 958–965.
133. Corey MR, Ergul EA, Cambria RP, et al. The natural history of splanchnic artery aneurysms and outcomes after operative intervention. *J Vasc Surg* 2016; 63: 949–957.
134. La Chapelle CF, Schutte JM, Schuitemaker NW, et al. Maternal mortality attributable to vascular dissection and rupture in the Netherlands: A nationwide confidential enquiry. *BJOG* 2012; 119: 86–93.
135. Khurana J, Spinello IM. Splenic artery aneurysm rupture: A rare but fatal cause for peripartum collapse. *J Intensive Care Med* 2013; 28: 131–133.
136. Hellmund A, Meyer C, Fingerhut D, et al. Rupture of renal artery aneurysm during late pregnancy: Clinical features and diagnosis. *Arch Gynecol Obstet* 2016; 293: 505–508.
137. De Bruyne B, Manoharan G, Pijls NH, et al. Assessment of renal artery stenosis severity by pressure gradient measurements. *J Am Coll Cardiol* 2006; 48: 1851–1855.
138. Wang LC, Scott DJ, Clemens MS, et al. Mechanism of stent failure in a patient with fibromuscular dysplasia following renal artery stenting. *Ann Vasc Surg* 2015; 29: 123.e19–21.
139. Raju MG, Bajzer CT, Clair DG, et al. Renal artery stent fracture in patients with fibromuscular dysplasia: A cautionary tale. *Circ Cardiovasc Interv* 2013; 6: e30–31.
140. Lacombe M, Ricco JB. Surgical revascularization of renal artery after complicated or failed percutaneous transluminal renal angioplasty. *J Vasc Surg* 2006; 44: 537–544.
141. Trinquart L, Mounier-Vehier C, Sapoval M, et al. Efficacy of revascularization for renal artery stenosis caused by fibromuscular dysplasia. A systematic review and meta-analysis. *Hypertension* 2010; 56: 525–532.
142. Al-Hussaini A, Adlam D. Spontaneous coronary artery dissection. *Heart* 2017; 103: 1043–1051.
143. Saw J, Mancini GBJ, Humphries KH. Contemporary review on spontaneous coronary artery dissection. *J Am Coll Cardiol* 2016; 68: 297–312.
144. Tweet MS, Gulati R, Hayes SN. Spontaneous coronary artery dissection. *Curr Cardiol Rep* 2016; 18: 60.

145. Tweet MS, Eleid MF, Best PJ, et al. Spontaneous coronary artery dissection: Revascularization versus conservative therapy. *Circ Cardiovasc Interv* 2014; 7: 777–786.
146. Saw J, Aymong E, Sedlak T, et al. Spontaneous coronary artery dissection: Association with predisposing arteriopathies and precipitating stressors and cardiovascular outcomes. *Circ Cardiovasc Interv* 2014; 7: 645–655.
147. Lettieri C, Zavalloni D, Rossini R, et al. Management and long-term prognosis of spontaneous coronary artery dissection. *Am J Cardiol* 2015; 116: 66–73.
148. Faden MS, Bottega N, Benjamin A, et al. A nationwide evaluation of spontaneous coronary artery dissection in pregnancy and the puerperium. *Heart* 2016; 102: 1974–1979.
149. Rogowski S, Maeder MT, Weilenmann D, et al. Spontaneous coronary artery dissection: Angiographic follow-up and long-term clinical outcome in a predominantly medically treated population. *Catheter Cardiovasc Interv* 2017; 89: 59–68.
150. Nakashima T, Noguchi T, Haruta S, et al. Prognostic impact of spontaneous coronary artery dissection in young female patients with acute myocardial infarction: A report from the Angina Pectoris-Myocardial Infarction Multicenter Investigators in Japan. *Int J Cardiol* 2016; 207: 341–348.
151. McGrath-Cadell L, McKenzie P, Emmanuel S, et al. Outcomes of patients with spontaneous coronary artery dissection. *Open Heart* 2016; 3: e000491.
152. Roura G, Ariza-Sole A, Rodriguez-Caballero IF, et al. Noninvasive follow-up of patients with spontaneous coronary artery dissection with CT angiography. *JACC Cardiovasc Imaging* 2016; 9: 896–897.
153. Alfonso F, Paulo M, Lennie V, et al. Spontaneous coronary artery dissection: Long-term follow-up of a large series of patients prospectively managed with a 'conservative' therapeutic strategy. *JACC Cardiovasc Interv* 2012; 5: 1062–1070.
154. Ito H, Taylor L, Bowman M, et al. Presentation and therapy of spontaneous coronary artery dissection and comparisons of postpartum versus nonpostpartum cases. *Am J Cardiol* 2011; 107: 1590–1596.
155. Motreff P, Malcles G, Combaret N, et al. How and when to suspect spontaneous coronary artery dissection: Novel insights from a single-centre series on prevalence and angiographic appearance. *EuroIntervention* 2017; 12: e2236–e2243.
156. Vanzetto G, Berger-Coz E, Barone-Rochette G, et al. Prevalence, therapeutic management and medium-term prognosis of spontaneous coronary artery dissection: Results from a database of 11,605 patients. *Eur J Cardiothorac Surg* 2009; 35: 250–254.
157. Mortensen KH, Thuesen L, Kristensen IB, et al. Spontaneous coronary artery dissection: A Western Denmark Heart Registry study. *Catheter Cardiovasc Interv* 2009; 74: 710–717.
158. Rashid HNZ, Wong DTL, Wijesekera H, et al. Incidence and characterisation of spontaneous coronary artery dissection as a cause of acute coronary syndrome – A single-centre Australian experience. *Int J Cardiol* 2016; 202: 336–338.
159. Barber-Chamoux N, Souteyrand G, Combaret N, et al. Contribution of optical coherence tomography imaging in management of iatrogenic coronary dissection. *Cardiovasc Revasc Med* 2016; 17: 138–142.
160. Elkayam U, Jalnapurkar S, Barakkat MN, et al. Pregnancy-associated acute myocardial infarction: A review of contemporary experience in 150 cases between 2006 and 2011. *Circulation* 2014; 129: 1695–1702.
161. Saw J, Aymong E, Mancini GB, et al. Nonatherosclerotic coronary artery disease in young women. *Can J Cardiol* 2014; 30: 814–819.
162. Desai S, Sheppard MN. Sudden cardiac death: Look closely at the coronaries for spontaneous dissection which can be missed. A study of 9 cases. *Am J Forensic Med Pathol* 2012; 33: 26–29.
163. Goel K, Tweet M, Olson TM, et al. Familial spontaneous coronary artery dissection: Evidence for genetic susceptibility. *JAMA Intern Med* 2015; 175: 821–826.
164. Alfonso F, Canales E, Aleong G. Spontaneous coronary artery dissection: Diagnosis by optical coherence tomography. *Eur Heart J* 2009; 30: 385.
165. Saw J, Mancini GB, Humphries K, et al. Angiographic appearance of spontaneous coronary artery dissection with intramural hematoma proven on intracoronary imaging. *Catheter Cardiovasc Interv* 2016; 87: E54–61.
166. Saw J. Coronary angiogram classification of spontaneous coronary artery dissection. *Catheter Cardiovasc Interv* 2014; 84: 1115–1122.
167. Tweet MS, Hayes SN, Pitta SR, et al. Clinical features, management, and prognosis of spontaneous coronary artery dissection. *Circulation* 2012; 126: 579–588.
168. Hayes SN, Kim ESH, Saw J, et al. Spontaneous coronary artery dissection: Current state of the science: A scientific statement from the American Heart Association. *Circulation* 2018; 137: e523–e557.
169. Adlam D, Alfonso F, Maas A, et al. European Society of Cardiology, acute cardiovascular care association, SCAD study group: A position paper on spontaneous coronary artery dissection. *Eur Heart J* 2018; 39: 3353–3368.
170. Pate GE, Lowe R, Buller CE. Fibromuscular dysplasia of the coronary and renal arteries? *Catheter Cardiovasc Interv* 2005; 64: 138–145.
171. Saw J, Poulter R, Fung A, et al. Spontaneous coronary artery dissection in patients with fibromuscular dysplasia: A case series. *Circ Cardiovasc Interv* 2012; 5: 134–137.
172. Toggweiler S, Puck M, Thalhammer C, et al. Associated vascular lesions in patients with spontaneous coronary artery dissection. *Swiss Med Wkly* 2012; 142: w13538.
173. Prasad M, Tweet MS, Hayes SN, et al. Prevalence of extracoronary vascular abnormalities and fibromuscular dysplasia in patients with spontaneous coronary artery dissection. *Am J Cardiol* 2015; 115: 1672–1677.
174. Saw J, Ricci D, Starovoytov A, et al. Spontaneous coronary artery dissection: Prevalence of predisposing conditions including fibromuscular dysplasia in a tertiary center cohort. *JACC Cardiovasc Interv* 2013; 6: 44–52.
175. Henkin S, Negrotto SM, Tweet MS, et al. Spontaneous coronary artery dissection and its association with heritable connective tissue disorders. *Heart* 2016; 102: 876–881.
176. Van Twist DJ, de Leeuw PW, Kroon AA. Coronary tortuosity: A clue to the diagnosis of fibromuscular dysplasia? *Am J Hypertens* 2017; 30: 776–780.
177. Garcia RA, deRoux SJ, Axiotis CA. Isolated fibromuscular dysplasia of the coronary ostium: A rare cause of sudden death. Case report and review of the literature. *Cardiovasc Pathol* 2015; 24: 327–331.
178. Maresi E, Becchina G, Ottoveggio G, et al. Arrhythmic sudden cardiac death in a 3-year-old child with intimal fibroplasia of coronary arteries, aorta, and its branches. *Cardiovasc Pathol* 2001; 10: 43–48.
179. Lee AH, Gray PB, Gallagher PJ. Sudden death and regional left ventricular fibrosis with fibromuscular dysplasia of small intramyocardial coronary arteries. *Heart* 2000; 83: 101–102.
180. Ropponen KM, Alafuzoff I. A case of sudden death caused by fibromuscular dysplasia. *J Clin Pathol* 1999; 52: 541–542.

181. Burke AP, Virmani R. Intramural coronary artery dysplasia of the ventricular septum and sudden death. *Hum Pathol* 1998; 29: 1124–1127.
182. Jing HL, Hu BJ. Sudden death caused by stricture of the sinus node artery. *Am J Forensic Med Pathol* 1997; 18: 360–362.
183. Imamura M, Yokoyama S, Kikuchi K. Coronary fibromuscular dysplasia presenting as sudden infant death. *Arch Pathol Lab Med* 1997; 121: 159–161.
184. Nichols G 2nd, Davis G, Lefkowitz J. Sudden death due to fibromuscular dysplasia of the sinoatrial nodal artery. *J Ky Med Assoc* 1989; 87: 504–505.
185. Burke AP, Farb A, Tang A, et al. Fibromuscular dysplasia of small coronary arteries and fibrosis in the basilar ventricular septum in mitral valve prolapse. *Am Heart J* 1997; 134: 282–291.
186. Burke AP, Subramanian R, Smialek J, et a. Nonatherosclerotic narrowing of the atrioventricular node artery and sudden death. *J Am Coll Cardiol* 1993; 21: 117–122.
187. Zack F, Kutter G, Blaas V, et al. Fibromuscular dysplasia of cardiac conduction system arteries in traumatic and nonnatural sudden death victims aged 0 to 40 years: A histological analysis of 100 cases. *Cardiovasc Pathol* 2014; 23: 12–16.
188. Hill SF, Sheppard MN. Non-atherosclerotic coronary artery disease associated with sudden cardiac death. *Heart* 2010; 96: 1119–1125.
189. Brodsky SV, Ramaswamy G, Chander P, et al. Ruptured cerebral aneurysm and acute coronary artery dissection in the setting of multivascular fibromuscular dysplasia: A case report. *Angiology* 2007; 58: 764–767.
190. Lie JT, Berg KK. Isolated fibromuscular dysplasia of the coronary arteries with spontaneous dissection and myocardial infarction. *Hum Pathol* 1987; 18: 654–656.
191. Makino Y, Inokuchi G, Yokota H, et al. Sudden death due to coronary artery dissection associated with fibromuscular dysplasia revealed by postmortem selective computed tomography coronary angiography: A case report. *Forensic Sci Int* 2015; 253: e10–e15.
192. Mather PJ, Hansen CL, Goldman B, et al. Postpartum multivessel coronary dissection. *J Heart Lung Transplant* 1994; 13: 533–537.
193. Michelis KC, Olin JW, Kadian-Dodov D, et al. Coronary artery manifestations of fibromuscular dysplasia. *J Am Coll Cardiol* 2014; 64: 1033–1046.
194. Camuglia A, Manins V, Taylor A, et al. Case report and review: Epicardial coronary artery fibromuscular dysplasia. *Heart Lung Circ* 2009; 18: 151–154.
195. Saw J, Bezerra H, Gornik HL, et al. Angiographic and intracoronary manifestations of coronary fibromuscular dysplasia. *Circulation* 2016; 133: 1548–1559.
196. Vance CJ, Taylor RN, Craven TE, et al. Increased prevalence of preeclampsia among women undergoing procedural intervention for renal artery fibromuscular dysplasia. *Ann Vasc Surg* 2015; 29: 1105–1110.
197. Berra E, Dominiczak AF, Touyz RM, et al. Management of a pregnant woman with fibromuscular dysplasia. *Hypertension* 2018; 71: 540–547.
198. Headache Classification Committee of the International Headache Society (IHS). The International Classification of Headache Disorders, 3rd edition. *Cephalalgia* 2018; 38: 1–211.
199. Kim EN, Lamb K, Relles D, et al. Median arcuate ligament syndrome—Review of this rare disease. *JAMA Surg* 2016; 151: 471–477.